

# Intrusion and Maintenance of Maxillary Incisors by Unilateral Orthodontic Anchorage Obtained Through Dental Implants Placed in Grafted Sinus: 16-Year Follow-Up of a Case

## Maksiller Sinüse Greft Kullanılarak Yerleştirilen Dental İmplantlar Yardımıyla Maksiller Kesicilerin İntrüzyonu: 16 Yıllık Takibin Olgu Sunumu

 Tosun TOSUN<sup>a</sup>,  Ahmet Özlem KELEŞ<sup>b</sup>,  Ufuk OK<sup>c</sup>

<sup>a</sup>Department of Oral and Maxillofacial Surgery, İstanbul Aydın University Faculty of Dentistry, İstanbul, Türkiye

<sup>b</sup>Department of Orthodontics, İstanbul Aydın University Faculty of Dentistry, İstanbul, Türkiye

<sup>c</sup>Department of Orthodontics, İstanbul Gelişim University Faculty of Dentistry, İstanbul, Türkiye

**ABSTRACT** This case report shows stationary orthodontic load bearing capacity of dental implants placed in grafted maxillary sinus. The treatment plan aimed to restore missing teeth by a fixed partial implant-retained prosthesis and to treat orthodontic alignment by the aid of the same prosthesis. A 39-years old male patient with unilaterally missing teeth in the maxilla and remaining crowded teeth exhibited poor oral hygiene. The treatment planning involved replacement of missing teeth by dental implants following sinus grafting and subsequent orthodontic correction by means of a newly designed implant retained prosthesis with reciprocal arms which give maximal anchorage to intrude maxillary incisors. Implants were used for dual purpose: Replacement of missing teeth and fixed anchorage for orthodontics. Implants placed in a grafted maxillary sinus which were used as orthodontic anchorage units, they maintained osseointegration during orthodontic treatment under stationary forces. Dental implants in grafted maxillary sinus are able to bear stationary orthodontic forces.

**Keywords:** Bone implant interactions;  
sinus floor elevation; orthodontics

**ÖZET** Bu olgu sunumu, greftlenen maksiller sinüse yerleştirilen dental implantların sabit ortodontik yük taşıma kapasitesini göstermektedir. Tedavi planı, implant destekli protez ile eksik dişleri düzeltmeyi ve aynı protez yardımıyla ortodontik hizalamayı amaçlıyordu. Üst çenede tek taraflı eksik ve çapraşık dişleri olan 39 yaşında erkek hasta kötü ağız hijyeni ve azalmış fonksiyon şikâyeti ile kliniğe başvurdu. Tedavi planlaması, sinüs greftlenmesini takiben eksik dişlerin diş implantları ile tedavisi ve ardından maksiller kesici dişlerin intrüze edilmesi için maksimum ankraj sağlayan karşılıklı kollara sahip tasarlanmış implant tutuculu protez aracılığıyla ortodontik düzeltmeyi içeriyordu. İmplantlar 2 amaçla kullanıldı: Eksik dişlerin yerine konması ve ortodonti için sabit ankraj. Ortodontik ankraj ünitesi olarak kullanılan greftli maksiller sinüse yerleştirilen implantlar, ortodontik tedavi sırasında sabit kuvvetler altında osseo integrasyonu sürdürdüler. Greftli maksiller sinüsteki diş implantları, sabit ortodontik kuvvetler için kullanılabilir.

**Anahtar Kelimeler:** Kemik implant etkileşimleri;  
sinüs tabanı yükseltme; ortodonti

This case report shows stationary orthodontic load bearing capacity of dental implants placed in grafted maxillary sinus. Anchor-implant usage for orthodontic purposes are being described extensively in the literature.<sup>1-5</sup> Implant placements with orthodontic aims can be classified in four categories: Transitional mini screw implant applications, orthodontic

implants or dental implants in the retromolar area, palataly placed orthodontic implants or dental implants, dual purpose (orthodontic and subsequent prosthetic) dental implant usages. Rigid anchorage capability of metallic implants placed in jaw bones for orthodontic treatment purposes are being reported.<sup>5-8</sup> These encouraging results lead the idea of

**Correspondence:** Ufuk OK

Department of Orthodontics, İstanbul Gelişim University Faculty of Dentistry, İstanbul, Türkiye

**E-mail:** dtufukok@hotmail.com



Peer review under responsibility of Türkiye Klinikleri Journal of Dental Sciences.

**Received:** 16 May 2021 **Accepted:** 29 Jun 2021 **Available online:** 12 Jun 2021

2146-8966 / Copyright © 2022 by Türkiye Klinikleri. This is an open access article under the CC BY-NC-ND license (<http://creativecommons.org/licenses/by-nc-nd/4.0/>).

“unilateral stationary anchorage” possibility by means of dental implants in cases with asymmetric teeth crowding. The present treatment approach included the placement of unilateral implants in the sinus-grafted maxilla and subsequent orthodontic therapy with rigid anchorage. The aims were replacement of missing teeth, correction of misalignments, facilitate orthodontic treatment by dental implants, to observe the load bearing capacity of grafted bone in maxillary sinus under stationary forces, to test the orthodontic anchorage usage of implant-retained fixed partial denture (FPD).

## CASE REPORT

Findings are reported according to EQUATOR (CARE-case report) guidelines. Written informed consent was obtained from the patient. A 39-years old male Caucasian patient referred with complains of missing teeth, reduced masticatory function and aesthetics. Left side maxillary canine, premolars, 1<sup>st</sup> and 2<sup>nd</sup> molars were missing. Alveolar ridge in this area was vertically reduced and radiological examination revealed left maxillary sinus expansion through edentulous region (Figure 1). Residual bone

height to place implants was about 5mm and in order to compensate missing bone volume a sinus grafting procedure was decided.

Sinus grafting was performed on September 26<sup>th</sup>, 2000. Maxillary sinus elevation by lateral window approach and grafting by a mixture of 1.0 gr deproteinized xenograft (Bio-Oss, Geistlich Pharma AG, Wolhusen, Switzerland) and 0,5gr hydroxyapatite granules (Algipore, Friadent, Mannheim, Germany) was performed. Sinus graft healing period was elongated due to patient’s social needs and dental implants were placed nine months later, on 04 June 2001. Four implants (Frialit-2, Friadent, Mannheim, Germany) of 14 mm height and 4.5 to 5.5 mm diameters were placed in places of canine, 2<sup>nd</sup> bicuspid and 1<sup>st</sup>, 2<sup>nd</sup> molars (Figure 2). After six months of conventional implant healing period, on January 25<sup>th</sup>, 2002, establishment of osseointegration was detected by radiography and clinically after gingiva former operation by percussion test. Healed implants did not show any radiolucent peri-implant interface and percussion test revealed no pain, any mobility and sharp, ringing sound from all implants. Thus, implants were judged to be osseointegrated. After heal-

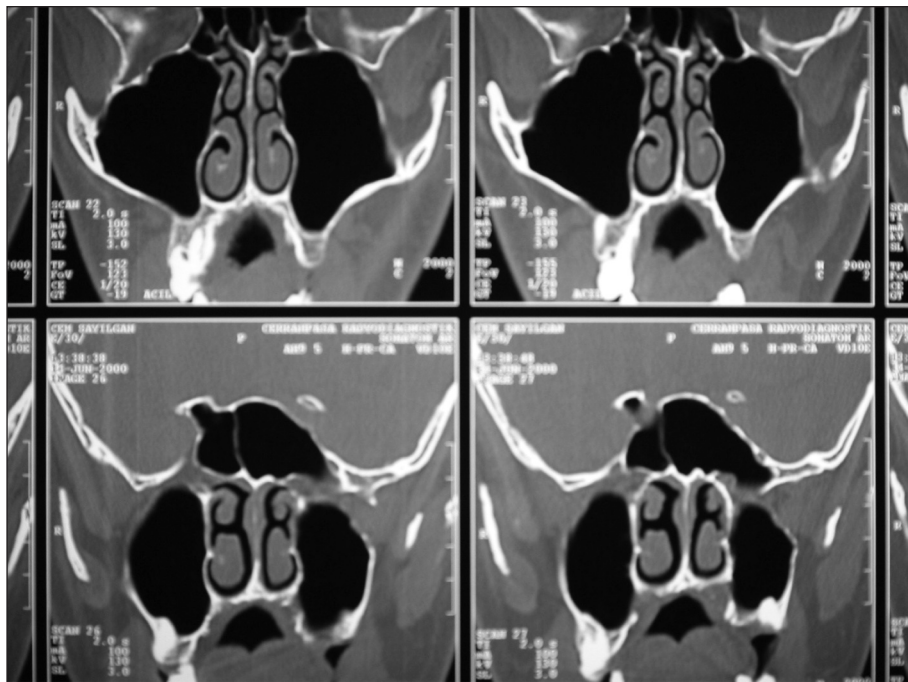


FIGURE 1: Left maxillary sinus expansion through edentulous region.

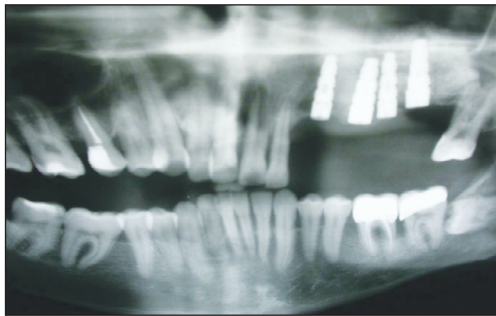


FIGURE 2: Implants were placed on June 2001.

ing period on April 4<sup>th</sup>, 2002, impressions were made. Subsequently, a screw-retained FPD was fabricated in order to obtain anchorage from dental implants to intrude maxillary incisors. This FPD was made for orthodontic purpose and was considered a transitional prosthesis and low-cost resin veneering material was preferred. The implant-retained FPD was designed to have two reciprocal arms in the palatal and buccal aspects through the incisors (Figure 3). Reciprocal arms were beginning from the mesial part of the canine and were aimed to retain elastics, and wired brackets attached to the incisors. The implant-retained FPD was placed on September 20<sup>th</sup>, 2002, thus the implants (placed on June 4<sup>th</sup>, 2001) were loaded 15 months after the surgical placement.

The patient was diagnosed with Class II div. 1 malocclusion with impinging deep bite and increased overjet. He presented incisal cant on the maxillary arch. Maxillary incisors were bonded with 0.018 slot size straight wire braces. Segmental arch wires were engaged between maxillary incisors with the wire sequence of 0.014NiTi, 0.016NiTi, 0.016 SS, 0.016x0.022NiTi and 0.016x0.022 SS. Vertical elastic force was applied from the maxillary left lateral incisor to the metal extension of the implant-retained FPD to intrude and correct the maxillary incisor's occlusal cant (Figure 4). The patient was seen monthly basis for the replacement of the wires and the elastic chains. After the correction of the incisal edge discrepancy by unilateral intrusion mechanics bilateral vertical force was applied to correct the deep bite. Active orthodontic treatment lasted for 10 months. Due to the intrusion, canine of the implant-retained FPD was remained over-leveled in respect to the lateral in-

cisor. Incisal lines of canine and bicuspid were counterer. For retention, fixed lingual retainer from upper lateral to lateral and Essix type clear retainer were delivered in August 1<sup>st</sup> 2003.

For better patient comfort, hygiene and esthetics a porcelain fused to metal (PFM) implant-retained FPD was fabricated. This cement-retained PFM was having a palatal retainer arm to preserve incisor's positions. Such implant-retained FPD was delivered in September 29<sup>th</sup> 2003 (Figure 5).

Treatment times in the present case were extended primarily due to the work conditions of the patient. Currently treatment times with dental implants are accelerated. Fifteen-years follow-up with implant-retained FPD since September 2003, revealed maintenance of osseointegration and peri-implant bone levels, preservation of intruded position of incisors (Figure 6).

Prosthetic design with reciprocal arms was an innovative solution to intrude incisors by means of a fixed appliance. Another detail is palatal retainer extension design thought for maintenance of alignment.

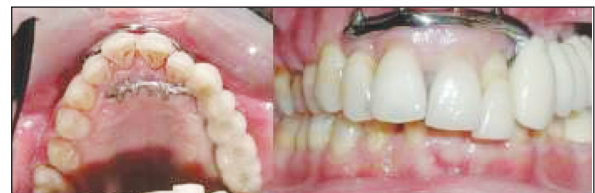

FIGURE 3: Implant-retained fixed partial denture was designed to have two reciprocal arms in the palatal and buccal aspects.

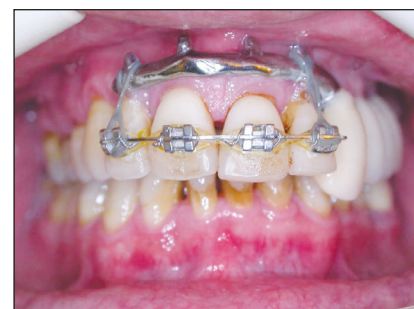

FIGURE 4: Vertical elastic force was applied from the maxillary left lateral incisor to the metal extension of the implant-retained fixed partial denture to intrude and correct the maxillary incisor's occlusal cant.

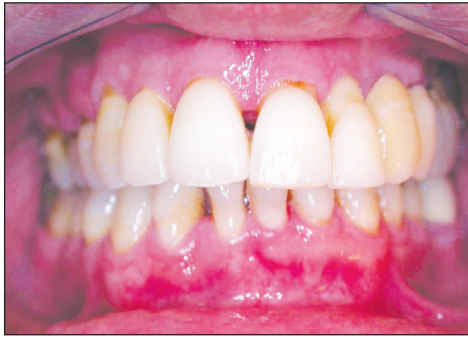

FIGURE 5: Implant retained prosthesis, September 2003.

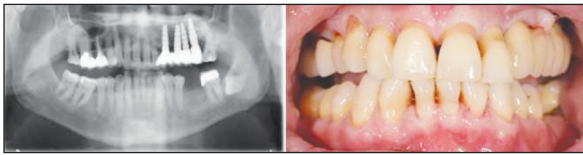

FIGURE 6: a) Peri-implant bone level maintenance in OPG taken in January 2019, b) Follow-up of the patient in January 2019.

## DISCUSSION

In the present case, implants were placed in a grafted sinus area and loaded by stationary forces during orthodontic treatment. Good prognosis of dental implants placed in grafted sinus areas were extensively reported in the literature.<sup>9-11</sup> According to our research in different databases, the only report regarding stationary anchorage by dental implants placed in grafted bone is made by Vitral et al. in 2009.<sup>12</sup> Unilateral anchorage by means of implants is also rarely reported.<sup>13-15</sup> The present case approves stationary load bearing capacity of dental implants in grafted maxillary sinus.

Multidisciplinary treatment approach enables to treat most difficult cases revealing innovative solutions by amalgamation of branch knowledges.

## MAIN POINTS

Implants placed in a grafted maxillary sinus which were used as orthodontic anchorage units, they maintained osseointegration during orthodontic treatment under stationary forces.

Dental implants in grafted maxillary sinus are able to bear stationary orthodontic forces.

The present case approves stationary load bearing capacity of dental implants in grafted maxillary sinus.

## AVAILABILITY OF DATA AND MATERIALS

The data that support the findings of this study are available from the corresponding author upon reasonable request from [tosuntosun@aydin.edu.tr](mailto:tosuntosun@aydin.edu.tr)

## Source of Finance

*During this study, no financial or spiritual support was received neither from any pharmaceutical company that has a direct connection with the research subject, nor from a company that provides or produces medical instruments and materials which may negatively affect the evaluation process of this study.*

## Conflict of Interest

*No conflicts of interest between the authors and / or family members of the scientific and medical committee members or members of the potential conflicts of interest, counseling, expertise, working conditions, share holding and similar situations in any firm.*

## Authorship Contributions

**Idea/Concept:** Tosun Tosun, Ahmet O Keleş; **Design:** Tosun Tosun, Ahmet O Keleş; **Control/Supervision:** Tosun Tosun, Ahmet O Keleş; **Data Collection and/or Processing:** Tosun Tosun, Ahmet O Keleş; **Analysis and/or Interpretation:** Tosun Tosun, Ahmet O Keleş; **Literature Review:** Tosun Tosun, Ufuk Ok; **Writing the Article:** Tosun Tosun, Ahmet O Keleş; **Critical Review:** Tosun Tosun; **References and Fundings:** Tosun Tosun; **Materials:** Tosun Tosun.

## REFERENCES

1. Park HS, Jeong SH, Kwon OW. Factors affecting the clinical success of screw implants used as orthodontic anchorage. *Am J Orthod Dentofacial Orthop.* 2006;130(1):18-25. [[Crossref](#)] [[PubMed](#)]
2. Huang LH, Shotwell JL, Wang HL. Dental implants for orthodontic anchorage. *Am J Orthod Dentofacial Orthop.* 2005;127(6):713-22. [[Crossref](#)] [[PubMed](#)]
3. Ohashi E, Pecho OE, Moron M, Lagravere MO. Implant vs screw loading protocols in orthodontics. *Angle Orthod.* 2006;76(4):721-7. [[PubMed](#)]
4. Reynders R, Ronchi L, Bipat S. Mini-implants in orthodontics: a systematic review of the literature. *Am J Orthod Dentofacial Orthop.* 2009;135(5):564.e1-19; discussion 564-5. [[Crossref](#)] [[PubMed](#)]
5. Kokich VG. Managing complex orthodontic problems: the use of implants for anchorage. *Semin Orthod.* 1996;2(2):153-60. [[Crossref](#)] [[PubMed](#)]
6. Cronin RJ Jr, Oesterle LJ. Implant use in growing patients. Treatment planning concerns. *Dent Clin North Am.* 1998;42(1):1-34. [[Crossref](#)] [[PubMed](#)]
7. Thilander B, Odman J, Gröndahl K, Friberg B. Osseointegrated implants in adolescents. An alternative in replacing missing teeth? *Eur J Orthod.* 1994;16(2):84-95. [[Crossref](#)] [[PubMed](#)]
8. Thilander B, Odman J, Lekholm U. Orthodontic aspects of the use of oral implants in adolescents: a 10-year follow-up study. *Eur J Orthod.* 2001;23(6):715-31. [[Crossref](#)] [[PubMed](#)]
9. Wallace SS, Froum SJ. Effect of maxillary sinus augmentation on the survival of endosseous dental implants. A systematic review. *Ann Periodontol.* 2003;8(1):328-43. [[Crossref](#)] [[PubMed](#)]
10. Pjetursson BE, Tan WC, Zwahlen M, Lang NP. A systematic review of the success of sinus floor elevation and survival of implants inserted in combination with sinus floor elevation. *J Clin Periodontol.* 2008;35(8 Suppl):216-40. [[Crossref](#)] [[PubMed](#)]
11. Thoma DS, Zeltner M, Hüsler J, Hämmerle CH, Jung RE. EAO Supplement Working Group 4-EAO CC 2015 Short implants versus sinus lifting with longer implants to restore the posterior maxilla: a systematic review. *Clin Oral Implants Res.* 2015;26 Suppl 11:154-69. [[Crossref](#)] [[PubMed](#)]
12. Vitral RW, da Silva Campos MJ, de Andrade Vitral JC, Santiago RC, Fraga MR. Orthodontic distalization with rigid plate fixation for anchorage after bone grafting and maxillary sinus lifting. *Am J Orthod Dentofacial Orthop.* 2009;136(1):109-14. [[Crossref](#)] [[PubMed](#)]
13. Gedrange T, Boening K, Harzer W. Orthodontic implants as anchorage appliances for unilateral mesialization: a case report. *Quintessence Int.* 2006;37(6):485-91. [[PubMed](#)]
14. Alani A, Bishop K, Knox J, Gravenor C. The use of implants for anchorage in the correction of unilateral crossbites. *Eur J Prosthodont Restor Dent.* 2010;18(3):123-7. [[PubMed](#)]
15. Ishihara Y, Kuroda S, Sugawara Y, Kurosaka H, Takano-Yamamoto T, Yamashiro T. Long-term stability of implant-anchored orthodontics in an adult patient with a Class II Division 2 malocclusion and a unilateral molar scissors-bite. *Am J Orthod Dentofacial Orthop.* 2014;145(4 Suppl):S100-13. [[Crossref](#)] [[PubMed](#)]