

Chard extract increased gastric sialic acid and ameliorated oxidative stress in valproic acid-administered rats

Burçin ALEV-TÜZÜNER^{1,2}, Sevim TUNALI³, Ünsal V. ÜSTÜNDAĞ⁴, Hazal İPEKÇİ⁵, Ebru EMEKLİ-ALTURFAN⁵, Tuğba TUNALI-AKBAY⁵, Refiye YANARDAĞ³, Ayşen YARAT⁵

Cite this article as:

Alev-Tüzüner, B., Tunalı, S., Üstündağ, Ü.V., İpekçi, H., Emekli-Alturfan, E., Tunalı-Akbay, T., Yanardağ, R., Yarat, A. (2023). Chard extract increased gastric sialic acid and ameliorated oxidative stress in valproic acid-administered rats. *Food and Health*, 9(2), 139-147. <https://doi.org/10.3153/FH23013>

¹ Istanbul Gelisim University, Faculty of Dentistry, Department of Basic Medical Sciences, Biochemistry, Istanbul, Türkiye

² Istanbul Gelisim University, Life Sciences and Biomedical Engineering Application and Research Centre, Istanbul, Türkiye

³ Istanbul University-Cerrahpaşa Faculty of Engineering, Department of Chemistry, Istanbul, Türkiye

⁴ Medipol University, Faculty of Medicine, Department of Medical Biochemistry, Istanbul, Türkiye

⁵ Marmara University, Faculty of Dentistry, Department of Basic Medical Sciences, Biochemistry, Istanbul, Türkiye

ORCID IDs of the authors:

B.A.T. 0000-0001-5122-4977

S.T. 0000-0003-3363-1290

Ü.V.Ü. 0000-0003-0804-1475

H.İ. 0000-0003-1193-168X

E.E.A. 0000-0003-2419-8587

T.T.A. 0000-0002-2091-9298

R.Y. 0000-0003-4185-4363

A.Y. 0000-0002-8258-6118

Submitted: 16.12.2022

Revision requested: 24.12.2022

Last revision received: 28.12.2022

Accepted: 31.12.2022

Published online: 23.03.2023

Correspondence:

Burçin ALEV-TÜZÜNER

E-mail: btuzuner@gelisim.edu.tr



© 2023 The Author(s)

Available online at

<http://jfhs.scientificwebjournals.com>

ABSTRACT

Valproic acid, one of the most used drugs for epilepsy patients, has some known side effects. Chard extract has many pharmacological activities. The study aims to evaluate whether valproic acid might interfere with oxidative metabolism in gastric tissue and whether chard ameliorates these effects. The Sprague Dawley rats were divided into four groups (n=8); control, chard-given control, valproic acid, and chard-given valproic acid. The aqueous extracts of chard leaves were given 1 h before the administration of valproic acid for 7 days. On the 8th day, the animals were sacrificed under anesthesia and gastric tissues were homogenized. When compared to the control group, valproic acid significantly increased malondialdehyde and catalase activity, while superoxide dismutase activity decreased. Chard administration increased glutathione and, sialic acid levels and decreased malondialdehyde levels and superoxide dismutase activity in the valproic acid group. Based on these findings, since chard increased gastric sialic acid levels, we may suggest that chard may protect gastric mucosa may be through its antioxidant effects.

Keywords: Gastric tissue, Valproic acid, Chard, Sialic acid, Oxidative stress

Introduction

The gastrointestinal mucus layer coats and lubricates the surface of gastrointestinal tract. It plays a role in defense against microorganism. The gel layer is also essential for maintenance of intestinal homeostasis as a participating in cell signaling pathways (Johansson et al., 2013). Mucus is composed of mucins that is synthesized and secreted by goblet cells in the intestinal cells. Mucin is composed of sialic acid (SA), fucose, galactose, N-acetylgalactosamine, and N-acetylglucosamine (Wagner et al., 2018).

Valproic acid (2-propyl valeric acid, VPA) is used to prevent seizures and to treat migraines, bipolar, anxiety, and mood disorders. It shows the antiepileptic effect by blocking ion channels and increasing neurotransmitter gamma-aminobutyric acid through several mechanisms. Also, since the demonstration of its function as an inhibitor of histone deacetylase, VPA was used as adjuvant therapy in neurodegenerative diseases, HIV, and cancer (Đikić et al., 2017).

Despite its reputation as a safe drug, VPA has many side effects that may lead to gastrointestinal disturbances, hepatotoxicity, neurological disturbances, weight gain, pancreatitis, teratogenic effects, and thrombocytopenia (Chateauvieux et al., 2010; Gezginci-Oktayoglu et al., 2016). Chronic usage of VPA has decreased the thickness of gastrointestinal mucosa, and muscle layers in the stomach and ileum, and gastrointestinal (GI) tract motility decreased in rats prenatally exposed to VPA (Kim et al., 2013). Furthermore, it is established that VPA is capable of increasing the reactive oxygen species (ROS) levels in various tissues (Cárdenas-Rodríguez et al., 2013; Ustundag et al., 2015). GI complaints are common in epileptic patients taking long-term anti-epileptic drug medication. Prevention of GI side effects is very important in terms of increasing the effectiveness of treatment and reducing seizure attacks depending on drug absorption and use in patients (Jahromi et al., 2011).

Plant extracts have become increasingly popular and are often preferred to synthetic pharmaceuticals. Chard (*Beta vulgaris* L. var. *cicla*; Chenopodiaceae) is a widely used plant in folk medicine. Chard extract has many pharmacological activities, including hypoglycemic, anti-inflammatory, antioxidant, anti-acetylcholinesterase, antitumor, hemostatic and hepatoprotective effects (Ozsoy-Sacan et al., 2004; Tunali et al., 2020). The reasons for these activities are vitamin C, vitamin E, glycosides, flavonoids, saponins, minerals, phospholipid, glycolipid, folic acid, carotenoids, and fatty acids components present in this plant (Ustundag et al., 2015; Kim et al., 2004; Trifunovic et al., 2015; Ertik et al., 2021). To our knowledge, a study on the effects of chard on gastric tissue

against VPA toxicity focusing on oxidant-antioxidant parameters and SA as an important component of mucin, which forms the protective layer of the stomach, has not been reported yet. Therefore, this study was focused on the alteration of oxidant and antioxidant systems and SA in gastric tissue in response to VPA administration and the role of chard in VPA-related tissue damage.

Materials and Methods

Preparation of Aqueous Chard Extract

The leaves of chard were collected from Istanbul, Turkey. Prof. Dr. Neriman Ozhatay (Faculty of Pharmacy, Istanbul University) identified the chard leaves. They were washed in distilled water before being dried at room temperature. 100 g of dried chard leaves were extracted by boiling with 1 L of distilled water for 8 hours. After the extract was filtered, its water was removed from the rotary evaporator. The chard extract was administered by gavage to rats for 7 days after being redissolved in water (Tunali et al., 2020).

Experimental Animals

The female Sprague Dawley rats were kept in constant laboratory conditions. The temperature was 25 ± 2 °C and the relative humidity range was 55 ± 8 % with a 12 h:12 h light/dark circle. The animals had a standard pellet diet and access to drinking water ad libitum. Experiments were approved by the Marmara University Animal Care and Use Committee (Ethics Committee Decision Number: 70.2014.mar)

Rats were divided into four groups (n=8) as; control (C); chard given control (100 mg/kg/day, by gavage) (C+Chard); VPA (500 mg/kg/day, intraperitoneally) and chard given VPA (VPA+Chard) (in same dose). For 7 days, chard leaf aqueous extracts were given 1 hour before VPA was given. After the rats were sacrificed under ether anesthesia on the eighth day of the experiment, gastric tissues were taken out. Gastric samples were homogenized in normal saline and were stored frozen at -20°C until the experiment day.

Biochemical Assays

In gastric tissue homogenates, malondialdehyde (MDA) levels were determined by thiobarbituric acid reaction spectrophotometrically at 532 nm for evaluation lipid peroxidation (LPO). LPO results were expressed as nmol MDA/mg protein (Yagi, 1984). GSH content in the supernatant was estimated by Ellman's reagent. Results were expressed as mg GSH/g protein (Beutler, 1975). SOD activity was measured by its capability to increase the effect of riboflavin-sensitized

photooxidation of o-dianisidine. Results were expressed as U/ mg protein (Mylorie et al., 1986). Catalase activity was assayed by measuring the decrease in the H₂O₂ concentration at 240 nm. Results were expressed as U/ mg protein (Aebi, 1984). SA content was measured by the TBA assay of Warren (Warren, 1959). Results were expressed as mg SA/g protein. The protein content in the supernatant was estimated according to Lowry et al., using Bovine Serum Albumin (BSA) as standard (Lowry et al., 1951). It was used to calculate other parameters' values as per protein.

Statistical Analysis

Statistical analysis was performed using GraphPad Prism 5.0 (GraphPad Software, San Diego, California, USA). Data were analysed using One-way ANOVA and post hoc Tukey tests. A p value of less than 0.05 was considered significant. Data were expressed as mean \pm standard deviation for each group. Principal component analysis (PCA) was also used to visualize the biochemical changes for all exposure conditions. PCA was performed using OriginPro 2022b (OriginLab Corp.).

Results and Discussion

VPA is a branched short-chain fatty acid and is nearly completely absorbed in the gastrointestinal system (Đikić et al., 2017). VPA causes mild to severe gastrointestinal, hematologic, neurological, dermatologic, mitochondrial, and metabolic toxicity. There is evidence of gastric injury in patients treated with VPA (Jahromi et al., 2011; Ozturk et al., 2017). VPA transforms to free acid (the valproate ion) in the GI tract (Dean et al., 1992). Gastric irritation/symptoms may be caused by its acidic nature. Also, in rats, VPA therapy has been linked to the development of oxidative stress in hepatotoxicity (Chang and Abbott, 2006). The term oxidative stress refers to describe an imbalance between ROS production and antioxidant defense activity. It plays a role in both chronic and acute GI diseases (Brown et al., 2014). The GI tract is important in the absorption of nutrients and the immunological response, and it also plays a role in the formation of ROS. At the same time, SOD, glutathione peroxidase, and CAT are the enzymes involved in protecting cells from the damaging effects of ROS (Vona et al., 2021). On the other hand, the mechanism of valproic acid-induced gastrotoxicity is still unclear.

Chard has many bioactive compounds such as phytopigments, flavonoids, and minerals. It is rich in dietary fibers, proteins, and antioxidants. Since it has also alpha lipoic acid, it decreases glucose levels and increases insulin sensitivity (Gamba et al., 2021).

In the current study, we have evaluated the effect of chard extract on the oxidative stress in the gastric tissue induced by VPA through the analysis of oxidant (LPO) and antioxidant (GSH, SOD, CAT, SA) parameters levels.

The gastric tissue MDA and GSH levels are presented in figure 1 and figure 2, respectively. The MDA levels significantly increased in the VPA group compared with the C groups ($p < 0.001$). Chard administration significantly decreased MDA levels both in the C+Chard and VPA+Chard groups ($p < 0.001$; $p < 0.001$). Administering chard significantly increased the GSH levels both in the C+Chard and VPA+Chard groups ($p < 0.001$; $p < 0.001$).

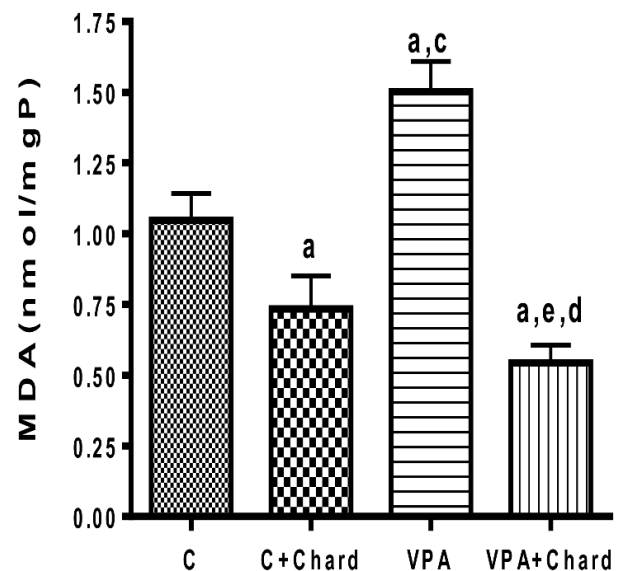


Figure 1. Gastric tissue MDA levels in the control, valproic acid, and chard given groups

Values were given as mean \pm standard deviation. C: Control group, C+Chard: Chard given control group, VPA: Valproic acid; VPA+Chard: Chard given VPA group. MDA: Malondialdehyde. ^a $p < 0.001$ significantly different from the C group; ^c $p < 0.001$ significantly different from the C+Chard group; ^d $p < 0.001$ significantly different from the VPA group; ^e $p < 0.01$ significantly different from the C+Chard group.

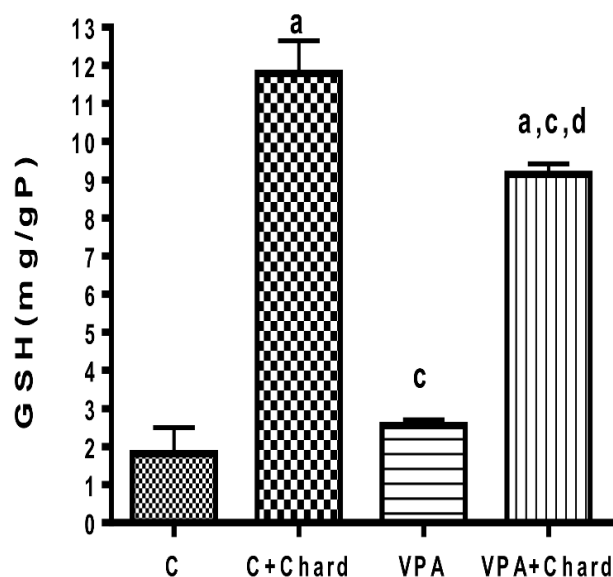


Figure 2. Gastric tissue GSH levels in the control, valproic acid and chard given groups

Values were given as mean \pm standard deviation. C: Control group, C+Chard: Chard given control group, VPA: Valproic acid; VPA+Chard: Chard given VPA group. GSH: Glutathione. ^a $p < 0.001$ significantly different from the C group; ^c $p < 0.001$ significantly different from the C+Chard group; ^d $p < 0.001$ significantly different from the VPA group.

The MDA is one of the products of LPO in the cells, which is used as an oxidative stress marker. Increased MDA is attributed to the enhanced production of ROS (Kwiecien et al., 2014). Compared with the VPA group, chard administration significantly decreased gastric MDA levels and increased GSH level in Chard+VPA group. The chard-induced increase of GSH levels is an antioxidative action because GSH acts as a free radical scavenger and repair the radical induced tissue damage (Ozsoy-Sacan et al., 2004). Also, our results suggest that the flavonoid content in chard is responsible for increased GSH levels in chard given groups. Dietary flavonoids stimulate antioxidant and detoxification defense system transcription through antioxidant response elements (Myhrstad et al., 2002).

As seen in figure 3, VPA caused a significant decrease in SOD activities of the VPA and VPA+Chard groups as compared to the C group ($p < 0.05$; $p < 0.001$). Chard administration decreased SOD activity significantly both in the C+Chard and VPA+Chard groups ($p < 0.05$; $p < 0.001$).

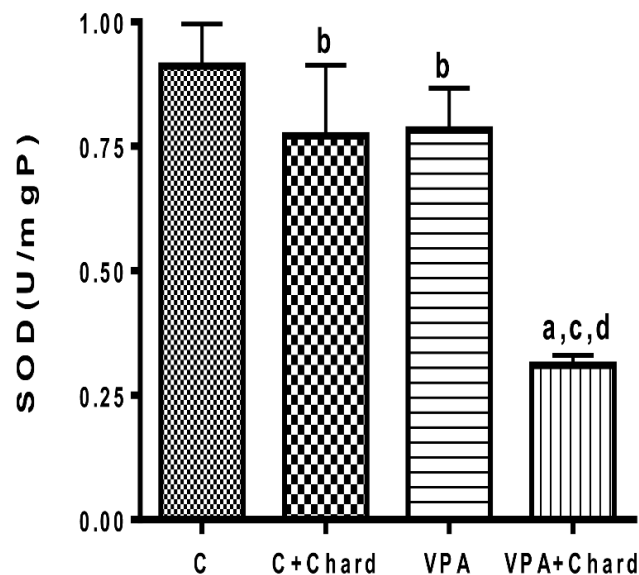


Figure 3. Gastric tissue SOD activity in the control, valproic acid, and chard given groups

Values were given as mean \pm standard deviation. C: Control group, C+Chard: Chard given control group, VPA: Valproic acid; VPA+Chard: Chard given VPA group. SOD: Superoxide dismutase. ^a $p < 0.001$ significantly different from the C group; ^b $p < 0.05$ significantly different from the C group; ^c $p < 0.001$ significantly different from the C+Chard group; ^d $p < 0.001$ significantly different from the VPA group.

The SOD is one of the antioxidants in the first line of defense against ROS to prevent oxidative stress. It converts the highly reactive O_2^- into the less reactive H_2O_2 and plays an important role in preventing oxidative damage (Vona et al., 2021). Our study found a decrease in the SOD activity in the chard given VPA rats. This suggests that O_2^- could not convert into H_2O_2 by SOD. The decrease in SOD activity is an indicator of mitochondrial dysfunction in the VPA-treated rat livers (Oztopuz et al., 2020). We also suggest that the decrease in SOD activity in the C+Chard group can be linked to other mechanisms.

The CAT activity in the gastric tissue is given in figure 4. VPA caused a significant increase in the CAT activities of VPA and VPA+Chard groups as compared to the C group ($p < 0.001$; $p < 0.001$). Chard administration increased the CAT activity significantly in the C+Chard group as compared to the C group ($p < 0.001$) but did not change it in the VPA+Chard group as compared to the VPA group ($p > 0.05$).

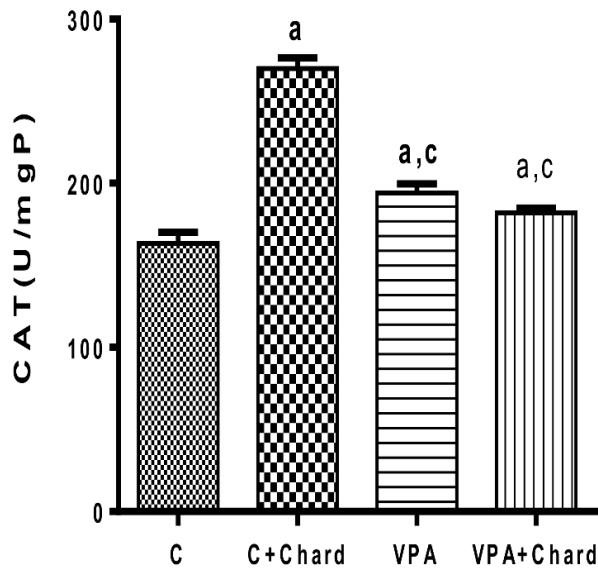


Figure 4. Gastric tissue CAT activity in the control, valproic acid, and chard given groups

Values were given as mean \pm standard deviation. C: Control group, C+Chard: Chard given control group, VPA: Valproic acid; VPA+Chard: chard given VPA group. CAT: Catalase. ^a $p < 0.001$ significantly different from the C group; ^c $p < 0.001$ significantly different from the C+Chard group.

The CAT is an antioxidant enzyme that has the ability to convert H_2O_2 to H_2O and O_2 (Vona et al., 2021). In acidic media, as in the stomach, O_2^- spontaneously is converted to H_2O_2 and peroxy radicals. At pH 4.8, spontaneous dismutation occurs most quickly and H_2O_2 and O_2 are produced (Kaplan et al., 2012). Thus, CAT activity in chard-administrated tissues might be increased in the gastric tissue. Since CAT enzymes are known to improve the capacity of the cells to eliminate ROS, increased enzyme activities would be expected to cause a decrease in MDA in the VPA group (Ustundag et al., 2015). However, no such effect was observed in this study.

As can be seen in figure 5, SA levels were not significantly different when VPA and C groups were compared ($p > 0.05$). Chard administration significantly increased the SA levels both in the C+Chard and VPA+Chard groups ($p < 0.001$; $p < 0.001$). In the VPA+Chard group, SA levels were significantly increased compared to the C group ($p < 0.001$).

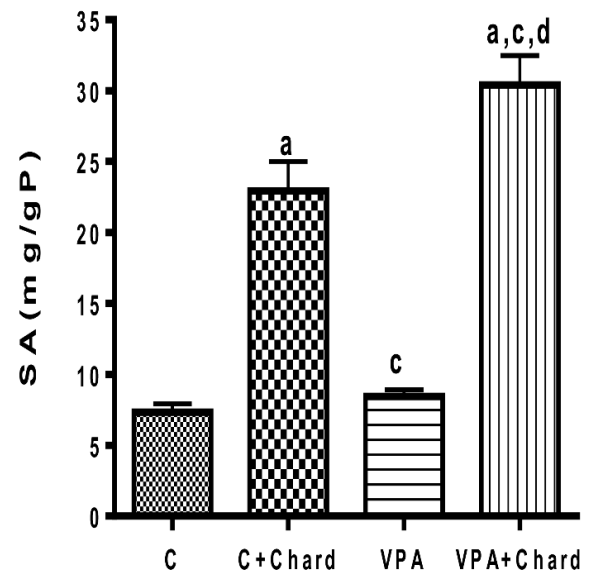


Figure 5. Gastric tissue SA levels in control, valproic acid and chard given groups

Values were given as mean \pm standard deviation. C: Control group, C+Chard: Chard given control group, VPA: Valproic acid; VPA+Chard: Chard given VPA group. SA: Total sialic acid. ^a $p < 0.001$ significantly different from the C group; ^c $p < 0.001$ significantly different from the C+Chard group, ^d $p < 0.001$ significantly different from the VPA group.

SA levels increased with chard administration in both the control and VPA groups. Chard may have an increased amount of gastric mucus. Polyphenolic-rich extract of *Potentilla mooniana* increased mucin activity by increasing the hexosamine and sialic acid content in the gastric tissue (Laloo et al., 2014). It has been suggested that SA has the antioxidant effect of mucin in the mucus layer covering the respiratory and gastrointestinal tracts against hydroxyl radicals. The study by Ogasawara et al. showed that hydroxyl radical produced by UV irradiation of hydrogen peroxide was scavenged by terminal SA residues in bovine submaxillary gland mucin (Ogasawara et al., 2007). It was revealed that SA also acts as an important defense factor of the gastric mucosa in the experimental model of gastritis in the rat (Hussein et al., 2016). SA-based strategies are recommended for the prevention and treatment of *Helicobacter pylori*, as SA has an antiadhesive effect on *H. pylori* on gastrointestinal epithelial cells and has been shown to reduce *H. pylori*-induced ROS production (Yang et al., 2013).

The SA usually presents as terminal components of glycoproteins, and these terminal residues impact mucus's charge, degradation, and rheological properties. Mucus is composed

of mucins that are synthesized and secreted by goblet cells in the intestinal cells. Mucin is composed of SA, fucose, galactose, N-acetylgalactosamine, and N-acetylglucosamine (Wagner et al., 2018). The SA on glycoproteins is released by sialidases such as sialate aldolase (Bhide and Colley, 2017). It has been found in bacteria and in mammalian cells. As a result of SA degradation, the cellular levels of SA increase. Hydrochloric acid secretion in the stomach's parietal cells is controlled by the gastric proton pump (H^+ , K^+ -ATPase). H^+ , K^+ -ATPase consists of the catalytic α subunit and the glycosylated β subunit. Intragastric pH regulates glycosylated β subunit, and inhibiting gastric hydrochloric acid secretion causes β subunit desialylation. It has been reported that the activity of H^+ , K^+ -ATPase is positively regulated by the SA of β subunit of the H^+ , K^+ -ATPase and the low pH reduced H^+ , K^+ -ATPase activity by cleaving the SA of β subunit (Fujii et al., 2016). This may be responsible for the increased SA levels found in the present study.

Flavonoids have attracted attention in the search due to their anti-inflammatory and antioxidant properties. Many studies have shown them to inhibit the gastric H^+K^+ -ATPase (Serafim et al., 2020; Al-Gabri et al., 2022). In the present study, SA levels increased significantly compared to the respective groups in the chard-given control and VPA groups. Since the chard has flavonoids and flavonoids have an inhibitory effect

on H^+K^+ -ATPase, it may be possible to suggest that the flavonoid contents of chard may be responsible for increased SA levels in this study.

Chard contains vitamins C and E that offer health benefits, and one of these benefits is that they are among the non-enzymatic antioxidants. Cytoprotective effects of vitamins C and E against different factors induced gastric mucosal damage were demonstrated (Dawud et al., 2014). In their studies, gastric mucus output was increased, and ulcer scores were decreased when treated with vitamins C and E. The antioxidant properties of vitamins protected the enzymatic and non-enzymatic antioxidants. In our study, the increase in the levels of SA with chard administration may be related to the fact that vitamins C and E increase the amount of mucus in the stomach. In addition, the cytoprotective effect of mucus and the antioxidant properties of vitamins may contribute to the gastroprotective effects of chard.

For each group, PCA was used to prove the correlation between biochemical results (Figure 6). PCA revealed that the first two components detailed around % 91.62 of the total variation in the experimental data (PC1: 66.83%, PC2: 24.79%). Primarily, CAT, GSH, and SA data clustered in the first component. These clusters were highly negatively correlated with MDA and SOD.

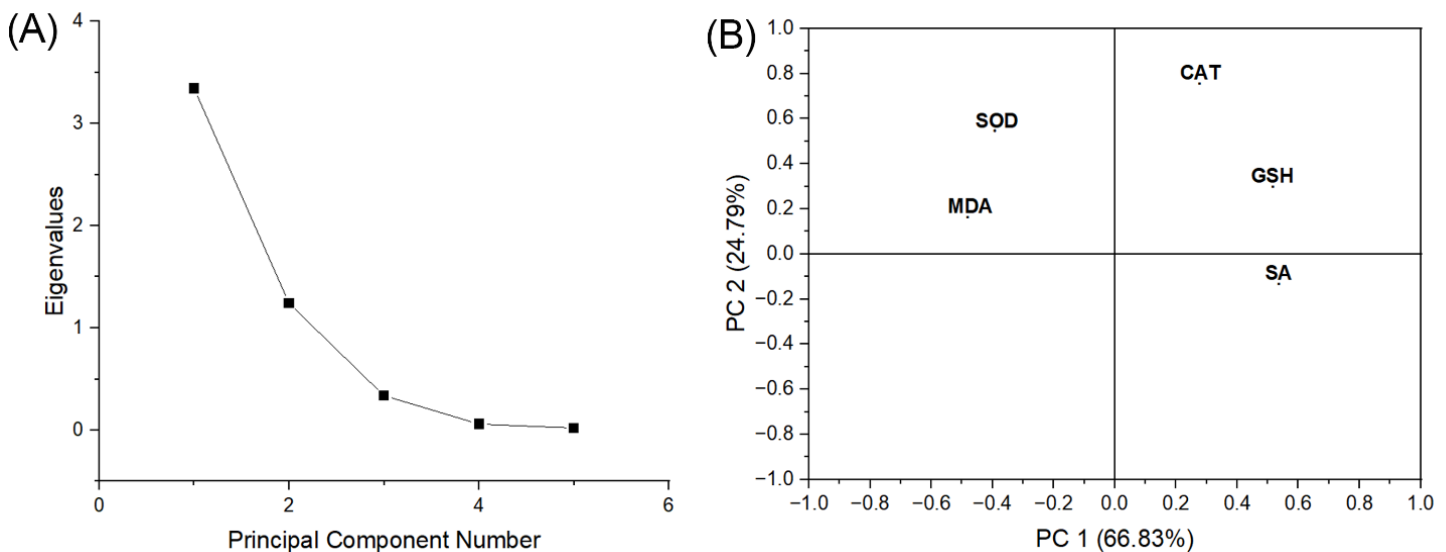


Figure 6. Principal component analysis (PCA) plot of biochemical parameters measured in the stomach (A). All biochemical results of stomach tissues indicator plotted as a function of two first components, explaining together 91.62% of information in the obtained dataset (B)

In the VPA group, we found a significant increase in MDA levels and a decrease in SOD activity, while no significant differences in GSH and SA levels compared to the control group. Also, it can be inferred that VPA produced an unbalanced oxidant/antioxidant cellular process in gastric tissue, with increased MDA and decreased SOD activity. Based on PCA, we observed in our study that antioxidant levels, except SOD, correlated negatively with oxidant levels. A previous study found an inverse relationship between SOD activity and MDA level in the tissues (Wang et al., 2005). But in this study, SOD activity and MDA level decreased significantly in the VPA+Chard group compared with the VPA group. This different oxidant-antioxidant status that occurs with the administration of chard extract may be related to mucus in the gastric tissue.

The increase of GSH and SA levels in chard given groups accompanied by an increase in CAT activity was effective in reducing lipid peroxidation.

This study has some limitations. No morphological or histological experiments were done, but this experiment focused only on biochemical changes in the gastric tissue. Also, H⁺, K⁺-ATPase activity was not examined. So, more extensive research on the chard's gastroprotective properties should be carried out in the future by analyses of H⁺, K⁺-ATPase activity, and molecular mechanisms of oxidative stress.

Conclusion

We may suggest that chard may protect gastric mucosa by increasing antioxidants and sialic acid levels. Therefore, the findings of this study may offer alternative treatment approaches and novel therapeutic targets for stomach damage caused by VPA.

Compliance with Ethical Standards

Conflict of interests: The author declares that for this article, they have no actual, potential, or perceived conflict of interest.

Ethics committee approval: Authors declare that this study does not include any experiments with human or animal subjects.

Funding disclosure: -

Acknowledgments: The authors would like to thank Prof. Dr. Neriman Özhatay for her help in the identification of the plant material.

Disclosure: -

References

- Aebi, H. (1984).** Catalase in vitro. *Methods Enzymology* 105, 121-126.
[https://doi.org/10.1016/s0076-6879\(84\)05016-3](https://doi.org/10.1016/s0076-6879(84)05016-3)
- Al-Gabri, N., Elnagar, G.M., Saghir, S.A.M., El-Shai-bany, A., Alnomasy, S.F., Althafar, Z.M., Elkomy, N.M.I.M., Elaasser, M.M., Abdoh, M.S., Yosri, M. (2022).** Preliminary study of the gastroprotective effect of *Aloe perryi* and date palm extracts on pyloric ligation-induced gastric ulcer in experimental rats. *BioMed Research International*, 9246785.
<https://doi.org/10.1155/2022/9246785>
- Beutler, E. (1975).** Glutathione: Red cell metabolism. In: Beutler E, editor. *A Manual of Biochemical Methods*. New York: Grune and Stratton Inc. 112-114.
- Bhide GP, Colley KJ. (2017).** Sialylation of N-glycans: Mechanism, cellular compartmentalization and function. *Histochemistry and Cell Biology* 147(2), 149-174.
<https://doi.org/10.1007/s00418-016-1520-x>
- Brown, K., Molcan, E., Rajendiran, E., Nusrat, A., Baker, J., Ruscheinsky, S., Gibson, D. (2014).** Free radicals in gastrointestinal disorders. In: Laher I, editor. *Systems biology of free radicals and antioxidants*. Berlin: Springer-Verlag. 1691-727.
- Cárdenas-Rodríguez, N., Coballase-Urrutia, E., Rivera-Espinosa, L., Romero-Toledo, A., Sampieri III, A., Ortega-Cuellar, D., Montesinos-Correa, H., Floriano-Sanchez, E., Carmona-Aparicio, L. (2013).** Modulation of antioxidant enzymatic activities by certain antiepileptic drugs (valproic acid, oxcarbazepine, and topiramate): Evidence in humans and experimental models. *Oxidative Medicine and Cellular Longevity*, 598493.
<https://doi.org/10.1155/2013/598493>
- Chang, T.K., Abbott, F.S. (2006).** Oxidative stress as a mechanism of valproic acid-associated hepatotoxicity. *Drug Metabolism Reviews*, 38(4), 627-639.
<https://doi.org/10.1080/03602530600959433>
- Chateauvieux, S., Morceau, F., Dicato, M., Diederich, M. (2010).** Molecular and therapeutic potential and toxicity of valproic acid. *Journal of Biomedicine and Biotechnology*, 479364.
<https://doi.org/10.1155/2010/479364>

Dawud, F.A., Mabrouk, M.A., Mohammed, A., Umar, I.A. (2014). Effect of vitamins C & E on aspirin induced gastric mucosal damage and oxidative stress. *Current Research Journal of Biological Sciences*, 6, 36-41. <https://doi.org/10.19026/CRJBS.6.5495>

Dean, J.C., Penry, J.K. (1992). Valproate. In: Resor SR, Kutt Jr H, editor. *The medical treatment of epilepsy*. Florida: CRC Press, Taylor&Francis Group. 265-279. <https://doi.org/10.1201/9781003066736>

Đikić, D., Jutrić, D., Dominko, K. (2017). The dual nature of the antiepileptic drug valproic acid, with possible beneficial effects in Alzheimer's disease. *Southeastern European Medical Journal*, 1(1), 74-89.

Ertik, O., Sacan, O., Kabasakal, L., Şener, G., Yanardag, R. (2021). Protective effect of chard extract on glycoprotein compounds and advanced oxidation protein product levels in diabetic rat livers. *Experimed*, 11(1), 27-32. <https://doi.org/10.26650/experimed.2021.879204>

Fujii, T., Watanabe, M., Shimizu, T., Takeshima, H., Kushiro, K., Takai, M., Sakai, H. (2016). Positive regulation of the enzymatic activity of gastric H⁺, K⁺-ATPase by sialylation of its β-subunit. *Biochimica et Biophysica Acta (BBA)-Biomembranes*, 1858(6), 1228-1235. <https://doi.org/10.1016/j.bbamem.2016.02.029>

Gamba, M., Raguindin, P.F., Asllanaj, E., Merlo, F., Glisic, M., Minder, B., Bussler, W., Metzger, B., Kern, H., Muka, T. (2021). Bioactive compounds and nutritional composition of swiss chard (*Beta vulgaris* L. var. *ciela* and *Flavescens*): A systematic review. *Critical Reviews in Food Science and Nutrition*, 61(20), 3465-3480. <https://doi.org/10.1080/10408398.2020.1799326>

Gezginici-Oktayoglu, S., Turkyilmaz, I.B., Ercin, M., Yanardag, R., Bolkent, S. (2016). Vitamin U has a protective effect on valproic acid-induced renal damage due to its anti-oxidant, anti-inflammatory, and anti-fibrotic properties. *Protoplasma*, 253(1), 127-135. <https://doi.org/10.1007/s00709-015-0796-3>

Hussein, S.A., Karousa, M.M., Amin, A., Awadalla, M.A. (2016). Evaluation of gastroprotective effect and anti-inflammatory role of resveratrol against gastric mucosal alterations in experimental model of gastritis in rats. *International Journal of Pharma Sciences*, 6(3), 1559-1570.

Jahromi, S.R., Togha, M., Fesharaki, S.H., Najafi, M., Moghadam, N.B., Kheradmand, J.A., Kazemi, H., Gorji, A. (2011). Gastrointestinal adverse effects of antiepileptic drugs in intractable epileptic patients. *Seizure*, 20(4), 343-346. <https://doi.org/10.1016/j.seizure.2010.12.011>

Johansson, M.E., Sjövall, H., Hansson, G.C. (2013). The gastrointestinal mucus system in health and disease. *Nature Reviews Gastroenterology & Hepatology*, 10(6), 352-361. <https://doi.org/10.1038/nrgastro.2013.35>

Kaplan, K.A., Odabasoglu, F., Halici, Z., Halici, M., Cirdirci, E., Atalay, F., Aydin, O., Cakir, A. (2012). Alpha-lipoic acid protects against indomethacin-induced gastric oxidative toxicity by modulating antioxidant system. *Journal of Food Science*, 77(11), H224-H230. <https://doi.org/10.1111/j.1750-3841.2012.02920.x>

Kim, I., Chin, Y.W., Lim, S.W., Kim, Y.C., Kim, J. (2004). Norisoprenoids and hepatoprotective flavone glycosides from the aerial parts of *Beta vulgaris* var. *ciela*. *Archives of Pharmacal Research*, 27(6), 600-603. <https://doi.org/10.1007/BF02980156>

Kim, J.W., Choi, C.S., Kim, K.C., Park, J.H., Seung, H., Joo, S.H., Yang, S.M., Shin, C.Y., Park, S.H. (2013). Gastrointestinal tract abnormalities induced by prenatal valproic acid exposure in rat offspring. *Toxicological Research* 29(3), 173-179. <https://doi.org/10.5487/TR.2013.29.3.173>

Kwiecien, S., Jasnos, K., Magierowski, M., Sliwowski, Z., Pajdo, R., Brzozowski, B., Mach, T., Wojcik, D., Brzozowski, T. (2014). Lipid peroxidation, reactive oxygen species and antioxidative factors in the pathogenesis of gastric mucosal lesions and mechanism of protection against oxidative stress-induced gastric injury. *Journal of Physiology and Pharmacology*, 65(5), 613-622.

Laloo D, Prasad SK, Sairam K, Hemalatha S. (2014). Gastroprotective activity of polyphenolic-rich extract of *potentilla mooniana*. *Pharmaceutical Biology*, 52(12), 1532-42. <https://doi.org/10.3109/13880209.2014.905794>

Lowry, O.H., Rosebrough, N.J., Farr, A.L., Randall, R. (1951). Protein Measurement with the Folin Phenol Reagent. *The Journal of Biological Chemistry*, 193(1), 265-275.

- Myhrstad, M.C., Carlsen, H., Nordström, O., Blomhoff, R., Moskaug, J.Ø. (2002). Flavonoids increase the intracellular glutathione level by transactivation of the γ -glutamylcysteine synthetase catalytical subunit promoter. *Free Radical Biology and Medicine*, 32(5), 386-393.
[https://doi.org/10.1016/s0891-5849\(01\)00812-7](https://doi.org/10.1016/s0891-5849(01)00812-7)
- Mylorie, A.A., Collins, H., Umbles, C., Kyle, J. (1986). Erythrocyte SOD activity and other parameters of copper status in rats ingesting lead acetate. *Toxicology and Applied Pharmacology*, 82(3), 512-520.
[https://doi.org/10.1016/0041-008x\(86\)90286-3](https://doi.org/10.1016/0041-008x(86)90286-3)
- Ogasawara, Y., Namai, T., Yoshino, F., Ishii, K. (2007). Sialic acid is an essential moiety of mucin as a hydroxyl radical scavenger. *FEBS letters*, 581(13), 2473-2477.
<https://doi.org/10.1016/j.febslet.2007.04.062>
- Ozsoy-Sacan, O., Karabulut-Bulan, O., Bolkent, S., Yanardag, R., Ozgey, Y. (2004). Effects of chard (*Beta vulgaris L. var cicla*) on the liver of the diabetic rats: A morphological and biochemical study. *Bioscience, Biotechnology, and Biochemistry*, 68(8), 1640-1648.
<https://doi.org/10.1271/bbb.68.1640>
- Oztopuz, O., Turkon, H., Buyuk, B., Coskun, O., Sehitoğlu, M.H., Ovali, M.A., Uzun, M. (2020). Melatonin ameliorates sodium valproate-induced hepatotoxicity in rats. *Molecular Biology Reports*, 47(1), 317-325.
<https://doi.org/10.1007/s11033-019-05134-6>
- Ozturk, O., Koklu, S., Koklu, H. (2017). Recurrent gastric polyposis in a patient using antiepileptic drugs for a long time. *Gastroenterology Nursing*, 40(2), 152-153.
<https://doi.org/10.1097/SGA.0000000000000281>
- Serafim, C., Araruna, M.E., Júnior, E.A., Diniz, M., Hiruma-Lima, C., Batista, L. (2020). A review of the role of flavonoids in peptic ulcer (2010–2020). *Molecules*, 25(22), 5431.
<https://doi.org/10.3390/molecules25225431>
- Trifunovic, S., Topalovic, A., Knezevic, M., Vajs, V. (2015). Free radicals and antioxidants: Antioxidative and other properties of swiss chard (*Beta vulgaris L. subsp. cicla*). *Agriculture & Forestry*, 61(2), 73-92.
<https://doi.org/10.17707/AgricultForest.61.2.06>
- Tunali, S., Cimen, E.S., Yanardag, R. (2020). The effects of chard on brain damage in valproic acid-induced toxicity. *Journal of Food Biochemistry*, 44(10), e13382.
<https://doi.org/10.1111/jfbc.13382>
- Ustundag, U.V., Tunali, S., Alev, B., Ipekci, H., Emekli-Alturfan, E., Akbay, T.T., Yanardag, R., Yarat, A.. (2015). Effects of chard (*Beta vulgaris L. var cicla*) on cardiac damage in valproic acid-induced toxicity. *Journal of Food Biochemistry* 40(2016), 132-139.
<https://doi.org/10.1111/jfbc.12202>
- Vona, R., Pallotta, L., Cappelletti, M., Severi, C., Matarrese, P. (2021). The impact of oxidative stress in human pathology: Focus on gastrointestinal disorders. *Antioxidants*, 10(2), 201.
<https://doi.org/10.3390/antiox10020201>
- Wagner, C.E., Wheeler, K.M., Ribbeck, K. (2018). Mucins and their role in shaping the functions of mucus barriers. *Annual Review of Cell and Developmental Biology*, 34,189–215.
<https://doi.org/10.1146/annurev-cellbio-100617-062818>
- Wang, S.H., Wang, Y.Z., Zhang, K.Y., Shen, J.H., Zhou, H.Q., Qiu, X.Y. (2005). Effect of superoxide dismutase and malondialdehyde metabolic changes on carcinogenesis of gastric carcinoma. *World Journal of Gastroenterology*, 11(28), 4305.
<https://doi.org/10.3748/wjg.v11.i28.4305>
- Warren, L. (1959). The thiobarbituric acid assay of sialic acids. *The Journal of Biological Chemistry*, 234, 1971-1975.
[https://doi.org/10.1016/S0021-9258\(18\)69851-5](https://doi.org/10.1016/S0021-9258(18)69851-5)
- Yagi, K. (1984). Assay for blood plasma or serum. *Methods in Enzymology*, 105, 328-331.
[https://doi.org/10.1016/S0076-6879\(84\)05042-4](https://doi.org/10.1016/S0076-6879(84)05042-4)
- Yang, J.C., Yang, H.C., Shun, C.T., Wang, T.H., Chien, C.T., Kao, J.Y. (2013). Catechins and sialic acid attenuate Helicobacter pylori-triggered epithelial Caspase-1 activity and eradicate Helicobacter pylori infection. *Evidence-Based Complementary and Alternative Medicine*, 2013, 248585.
<https://doi.org/10.1155/2013/248585>