



# Our Experience with Desmoid Tumors

## Desmoid Tümör Olgularındaki Deneyimimiz

Metin Keskin<sup>1</sup>, Muhammed Zübeyr Üçüncü<sup>2</sup>, Ecem Memişoğlu<sup>1</sup>, Adem Bayraktar<sup>1</sup>, Emre Balık<sup>3</sup>, Mehmet Türker Bulut<sup>1</sup>

<sup>1</sup>Istanbul University Istanbul Faculty of Medicine, Department of General Surgery, Istanbul, Turkey

<sup>2</sup>Istanbul Gelişim University, Institute of Health Sciences, Istanbul, Turkey

<sup>3</sup>Koç University Faculty of Medicine, Department of General Surgery, Istanbul, Turkey

### ABSTRACT

**Aim:** Desmoid tumors originating from musculoaponeurotic tissues progress locally and aggressively and these tumors do not metastasize to distant sites. The incidence shows increase in polyposis coli syndromes. In this article, we aimed to evaluate the results of the patients treated for desmoid tumors.

**Method:** Fifteen patients, who were diagnosed with desmoid tumors between the dates of 2000 and 2013, were evaluated in terms of demographical and clinical data, surgical interventions, complications and long-term follow-up results.

**Results:** The median age of patients was 35 (in between 20-51 years) years and 9 (60%) of them were women. Among 13 patients with polyposis syndrome, 6 (40%) underwent restorative proctocolectomy and 5 (33%) underwent total colectomy and ileorectal anastomosis. As 2 patients were accepted as inoperable, colon-oriented surgical intervention was not performed. Following the diagnosis of polyposis coli, the mean period of time between the surgery and development of desmoid tumor was found as 24.5 months (in between 4-48 months). Intra-abdominal region was found to be the most common tumor location (n=11 patients, 74%). As eight patients (54%) were inconvenient to the surgical excision, they were accepted as inoperable when they were diagnosed with desmoid tumor. Seven patients could undergo surgical resection, but all of them had recurrence in their follow-up. The mortality rate was 74% (n=11) and the mean survival rate was 79.7 months (in between 5-312 months). Multi-visceral organ transplantation was performed to one patient.

**Conclusion:** Following prophylactic colectomy at early ages, desmoid tumor has been the most common reason of the mortality in Polyposis syndrome. At the time of diagnosis, most patients are inoperable because of the invasion to adjacent organs, especially small-bowel meso. Although multi-visceral organ transplantation is one of the most complicated surgical procedures, it seems to be a convenient treatment option in patients with desmoid tumor.

**Keywords:** Desmoid tumors, polyposis coli, multi-visceral organ transplantation

### ÖZ

**Amaç:** Desmoid tümörler, mükuloaponevrotik dokulardan gelişen, lokal olarak agresif seyir gösteren ve uzak metastaz yapmayan tümörlerdir. Görülme sıklığı polipozis coli sendromlarında artış göstermektedir. Bu çalışmamızda, desmoid tümör nedeniyle tedavi ve takip ettiğimiz olguların sonuçlarının değerlendirilmesi amaçlandı.

**Yöntem:** Kliniklerimizde 2000-2013 yılları arasında desmoid tümör tanısı ile tedavisi yapılan 15 hastanın demografik ve klinik verileri, yapılan girişimler, komplikasyonlar ve uzun dönem takip sonuçları retrospektif olarak değerlendirildi.

**Bulgular:** On beş olgunun yaş ortalaması 35 (20-51) olup; 9'u (%60) kadındı. Polipozis sendromlu 13 hastadan altısına (%40) restoratif proktokolektomi, beşine (%33) ise tüm kolektomi ve ileorektal anastomoz ameliyatları yapıldı. İki olgu ise inoperabl olarak kabul edildiğinden, kolona yönelik cerrahi girişim yapılmadı. Polipozis coli tanısı sonrası, cerrahiye takiben desmoid tümör gelişmesi arasında geçen ortalama süre 24,5 (4-48) ay olarak tespit edildi. Tümörün yerleşim yerine bakıldığında, en sık batın içinde olduğu saptandı (n=11 olgu, %74). Sekiz (%54) olgu desmoid tümör tanısı konulduğunda cerrahi eksizyona uygun bulunmayarak inoperabl kabul edildi. Diğer yedi olguya (%46) cerrahi eksizyon yapılabilirken, bu hastaların hepsinde tümör nüksü izlendi. Hastalarının 11'i (%74) takipleri sürecinde kaybedildi. Ortalama sağkalm 79,7 ay (5-312) olarak saptandı. Bir olguya ise çoklu organ nakli yapıldı.

**Sonuç:** Desmoid tümörler, profilaktik kolektomilerin erken yaşta yapılmasını takiben polipozis coli hastalarının mortalitesinin en sık sebebi olmaya başlamıştır. Tanı anında, çoğu olgu çevre dokulara, özellikle ince barsak mezosuna, büyük kısmını invaze ettiğinden inoperabl'dır. Bu olgularda çoklu organ nakli her ne kadar komplike bir girişim gibi görünse de, şu an için uygun bir seçenek gibi durmaktadır.

**Anahtar Kelimeler:** Desmoid tümörler, polipozis coli, çoklu organ nakli



Address for Correspondence/Yazışma Adresi: Metin Keskin MD

Istanbul University Istanbul Faculty of Medicine, Department of General Surgery, Istanbul, Turkey

Phone: +90 212 587 18 61 E-mail: mtnkeskin@yahoo.com

Received/Geliş Tarihi: 22.07.2016 Accepted/Kabul Tarihi: 02.09.2016

©Turk J Colorectal Dis, Published by Galenos Publishing House.

This article is distributed under the terms of the "Creative Commons Attribution NonCommercial 4.0 International Licence (CC BY-NC 4.0)".

## Introduction

Polyposis coli syndromes (PS) are usually transmitted by autosomal dominant inheritance and they are responsible of 1% of colorectal cancers. The prevalence is 1/10000.<sup>1</sup> Polyps in the colon are mostly accompanied by gastric and duodenal polyps. Prophylactic total proctocolectomy (attenuated polyposis coli-total colectomy in selected cases) should be performed in all subjects, because colorectal cancer will develop up to the fifth decade.<sup>2</sup> Another tumor which is observed in patients with PS is desmoid tumors (DT). DT which is a soft tissue tumor arising from the musculoaponeurotic tissue is observed rarely in the normal population. It constitutes less than 3% of all soft tissue tumors and its incidence ranges between 2/1.000,000 and 4/1.000,000.<sup>3,4,5,6</sup> Although the etiology is not known exactly, abdominal surgery, pregnancy, use of estrogen and trauma are some of the causes which have been blamed.<sup>7</sup> DT which is observed rarely in the general population is encountered by colorectal surgeons as a complicated problem in 15% of the patients with PS.<sup>8</sup> This tumor which has no distant metastasis tends to infiltrate the surrounding structures by showing a local aggressive course.<sup>9</sup> The most efficient method in treatment is excision of the lesions with negative surgical border. However, the majority of the patients are not eligible for surgical excision at the time of diagnosis. Therefore, the mortality and morbidity rates related with DT are high, although it is a local disease. In this study, we aimed to evaluate the patients who were followed up and treated in our clinic because of DT with their long term outcomes.

## Materials and Methods

The database between the years of 2000 and 2013 in İstanbul University İstanbul Faculty of Medicine, Department of General Surgery was searched retrospectively and the patients who were treated with a diagnosis of DT were specified. The demographic data, symptoms, tumor localizations, accompanying findings, interventions performed (surgery or radiologic intervention under imaging guidance), complications and long-term follow-up outcomes of the patients specified were evaluated retrospectively.

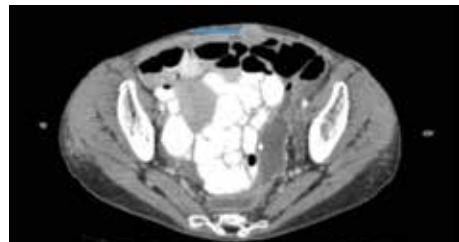
## Results

It was specified that 52 patients (27 women and 25 men) were operated with a diagnosis of DT between the years of 2000 and 2013 and 15 patients were investigated and treated because of DT in the same period. The mean age of the patients was found to be 35 (20-51) years; 9 (60%) of the patients were female and 6 (40%) were male. PS accompanied in 13 (86%) of these 15 patients and 2 (14%) cases were sporadic.

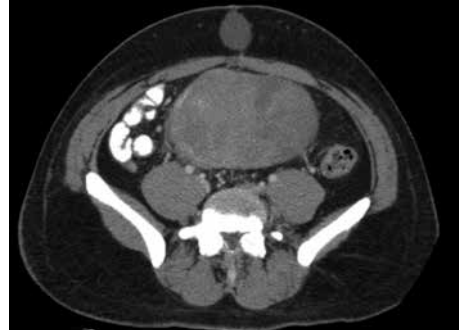
The diagnosis of PS was made after DT was specified in three (20%) patients. Restorative proctocolectomy was performed in 6 (40%) of 13 patients with PS and total colectomy and ileorectal anastomosis operation was performed in 5 (33%). Two patients who were diagnosed with DT before polyposis coli were considered inoperable and no surgical intervention directed to the colon was performed. The mean period between surgery following the diagnosis of PS and development of DT was found to be 24,5 (4-48) months. When the localization of the tumor was examined, it was found that DT was localized in the intraabdominal region in 11 patients (74%), in the abdominal wall in 2 patients (13%) and both in the intraabdominal region and in the abdominal wall in 2 patients (13%) (Figure 1a, 1b, 1c).

Eight (54%) patients were considered inoperable, because they were found to be ineligible for surgical excision when the diagnosis of DT was made. Surgical excision could be performed in the other 7 patients (46%) and recurrence of tumor was found in the long-term follow-up in all of these

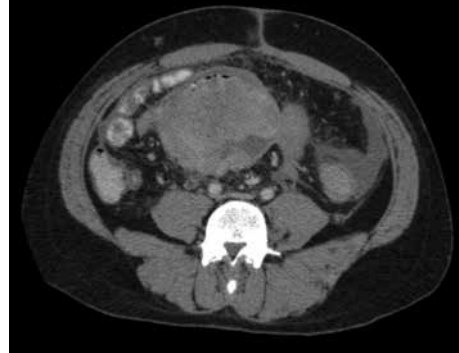A



B



C

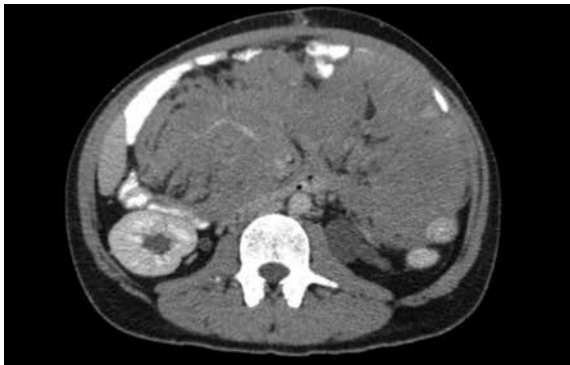

**Figure 1.** a) Desmoid tumor localized in the abdominal wall, b) A case of synchronous abdominal wall and intra-abdominal desmoid tumor, c) A case of intra-abdominal desmoid tumor

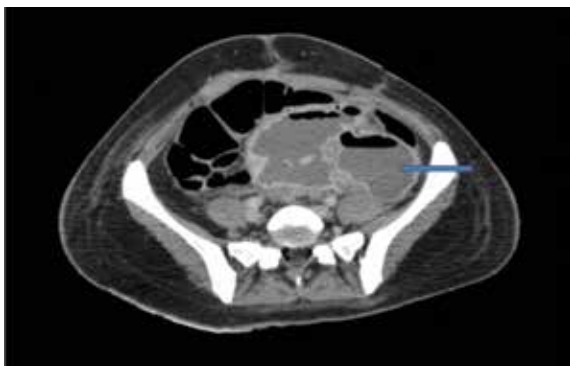
patients. Five (33%) of these patients were lost because of DT complications (bleeding, perforation). The reason that the patients in whom surgical intervention could not be performed were considered inoperable was the fact that the mass invaded a great part of the mesentery of the small intestine and surrounded the superior mesenteric artery (Figure 2).

Different medical therapies were tried in some of the patients who were considered inoperable (sulindac, estrogen, glivec, radiotherapy). However, complete cure or a chance for surgery with reduction in the mass could not be obtained in any of the patients. The most common complication following pain which was observed in these patients was development of interloop abscess [n=5 (%33) patients; Figure 3]. In these patients, a total of 15 percutaneous drainage procedure were performed under imaging guidance (ultrasonography or computerized tomography) with the objective of achieving palliation (Figure 4). Enterocutaneous fistula developed in two patients. Percutaneous nephrostomy was performed in a total of 3 patients and pigtail catheter was inserted in 3 patients because of ureter obstruction (Figure 5).

It was found that extra-abdominal involvement (bone tumor-osteoma) accompanied in a total of 4 patients (in the mandibula in one patient, in the cranium in one patient,



**Figure 2.** A case of desmoid tumor which has invaded the superior mesenteric artery

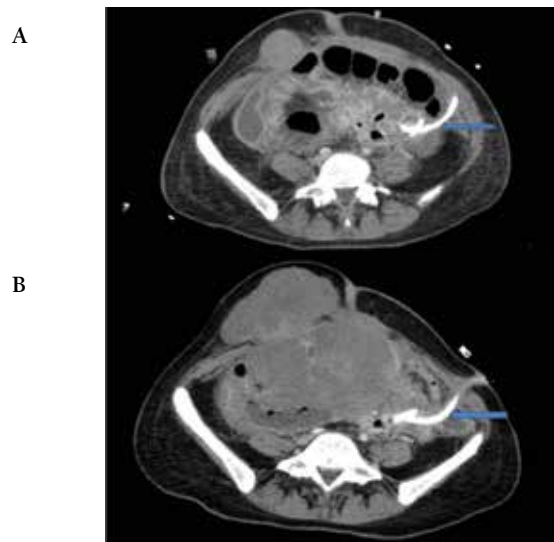


**Figure 3.** Interloop abscess which has developed secondary to desmoid tumor

in the vertebra in one patient and in the sacrum in one patient) (Figure 6).

Eleven (74%) of the patients with DT were lost during the follow-up period. The mean survival time after the diagnosis was found to be 79.7 months (5-312) in the patients who were lost. The demographic and clinical data of the patients are given in Table 1 and 2 in summary.

After unsatisfactory outcomes in our series we sent our 2 final DT patients whom we considered



**Figure 4.** Post-procedural images of patients with interloop abscess who underwent percutaneous drainage procedure under imaging guidance

**Table 1.** Demographic data summary

<b>Mean age</b>	<b>35 (20-51)</b>
Gender (Male/Female)	9/6
Localization	
Intra-abdominal	11 (74%)
Abdominal wall	2 (13%)
Abdominal wall+Intra-abdominal	2 (13%)
Colorectal intervention performed	
Restorative proctocolectomy	6 (40%)
Total colectomy-ileorectal anastomosis	5 (34%)
The time for development of desmoid tumor after colon surgery	24.5 (4-48) month
Number of patients who underwent desmoid tumor resection	7 (46%)
Radiological intervention	
Percutaneous drainage	5 (34%)
Percutaneous Nephrostomy	3 (20%)
Mortality	11 (74%)

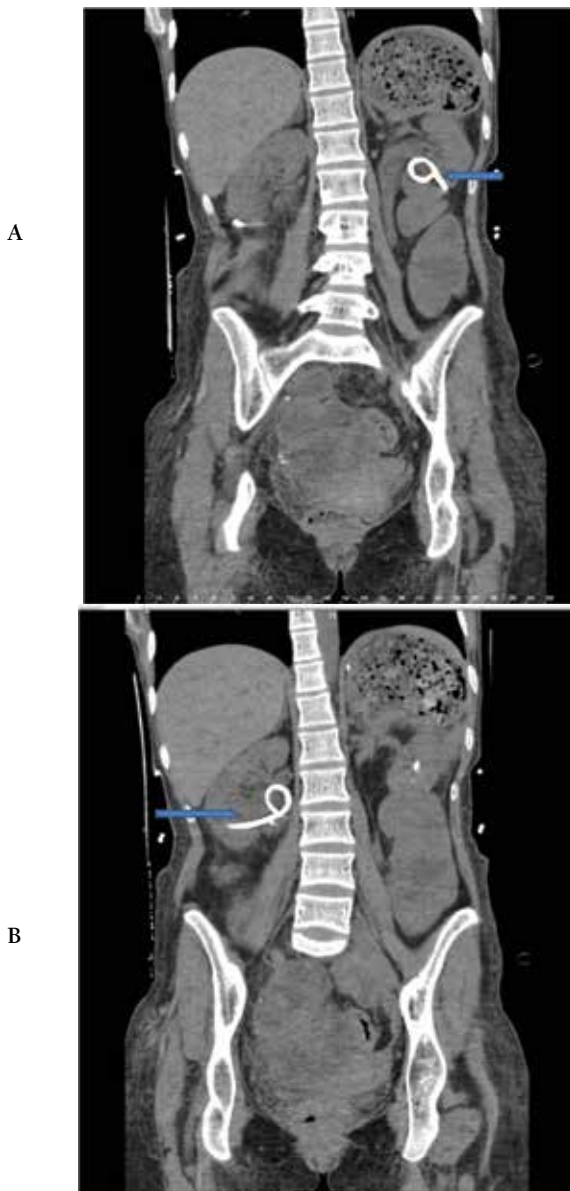
Table 2. Clinical data summary

Patient number	Age	Gender	Time of the diagnosis (1)	Colon surgery (2)	Time (3)	Desmoid tumor localization	Extra-abdominal involvement	Desmoid tumor resection	Non-surgical intervention	Recurrence	Mortality
1	20	Female	BCI	TAC	0	Intra-abdominal	Mandibula	Yes	No	Yes	Ex
2	21	Male	ACI	TAP	16	Abdominal Wall and intra-abdominal	No	Yes	No	Yes	Ex
3	50	Female	--	No polyposis coli	0	Abdominal Wall	No	Yes	No	Yes	Ex
4	37	Female	--	No polyposis coli	0	Abdominal Wall	Sacrum	Yes	No	Yes	Alive
5	24	Male	Simultaneous	Inop	0	Intra-abdominal	No	No	Percutaneous drainage	No	Ex
6	50	Male	ACI	TAP	16	Intra-abdominal	No	No	Percutaneous+Nefrostomy	No	Ex
7	39	Female	ACI	TAC	4	Intra-abdominal	No	No	No	No	Ex
8	42	Female	BCI	Inop	0	Abdominal Wall and intra-abdominal	Vertebra	Yes	Pigtail catheter	Yes	Ex
9	26	Female	ACI	TAP	36	Intra-abdominal	No	Yes	Percutaneous drainage	Yes	Ex
10	23	Female	ACI	TAC	48	Intra-abdominal	Cranium	Yes	Pigtail-Nefrostomy	Yes	Alive
11	38	Male	ACI	TAC	24	Intra-abdominal	No	No	Percutaneous drainage	No	Ex
12	32	Female	ACI	TAP	20	Intra-abdominal	No	No	Pigtail-Nefrostomy	No	Alive
13	41	Female	ACI	TAP	18	Intra-abdominal	No	No	Percutaneous drainage	No	Ex
14	51	Male	BCI	TAC	0	Intra-abdominal	No	No	No	No	Ex
15	30	Male	ACI	TAP	30	Intra-abdominal	No	No	No	No	Alive

1: BCI: Before colorectal intervention, ACI: after colorectal intervention

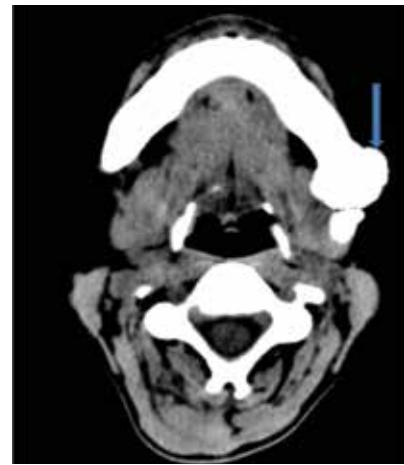
2: TAC: Total abdominal colectomy, TAP: total abdominal proctocolectomy

3: Time until development of desmoid tumor following colonic operation

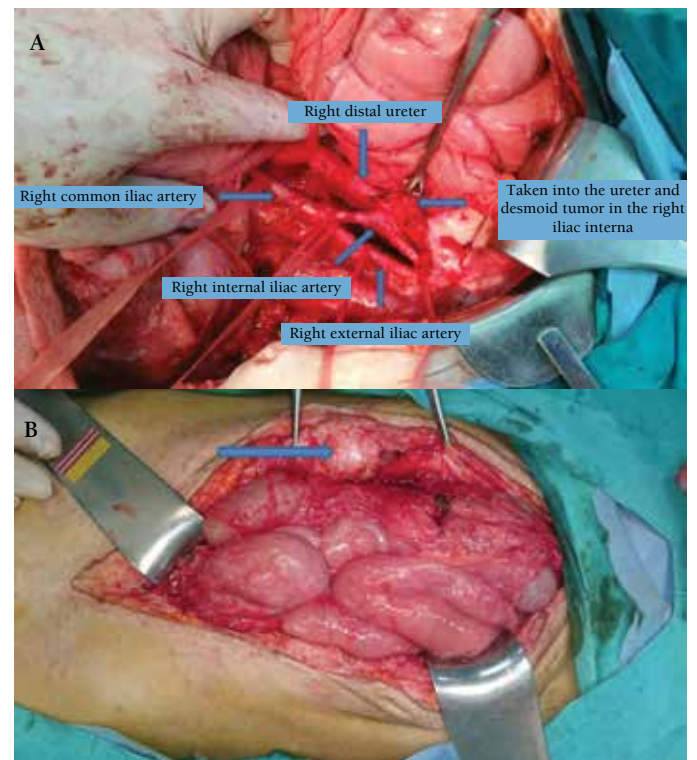


**Figure 5.** Post-procedural computerized tomography images of the patient who underwent bilateral percutaneous nephrostomy because of bilateral ureter obstruction secondary to desmoid tumor

inoperable to the United States of America by corresponding with the Social Security Institution and the Ministry of Health considering that cure could be obtained with multivisceral organ transplantation. Multivisceral organ transplantation (stomach, small bowel, colon and pancreas) was performed in our first patient in Miami in August 2013. This patient was followed up without recurrence for two years. Afterwards, DT recurrence was found including one with intra-abdominal localization (causing ureter obstruction) and six in the abdominal wall (Figure 7a and 7b). These masses were resected in our unit. This patient is being followed up without recurrence following this surgical intervention. Treatment of the second patient whom we sent to the same



**Figure 6.** Cranial computerized tomography image of a patient who had benign bone tumor in the left mandibula



**Figure 7. a, b)** Abdominal wall and intra-abdominal recurrences of desmoid tumor following multivisceral organ transplantation

center for transplantation is still continuing in the clinic in Miami and this patient is waiting for transplantation. Another patient which we referred for transplantation is still being followed up by us because of the problems which were experienced during official correspondence.

## Discussion

DT is a tumor arising from the mesenchymal tissue which occurs as a result of clonal proliferation of myofibroblasts. It was defined by McFarlane in 1832 for the first time as a

tumor occurring in the abdominal wall in a woman in the postpartum period. The term “desmoid tumor” was used by Mueller in 1838 for the first time.<sup>10,11</sup> The most prominent and typical properties include lack of metastasis and local aggressive course by way of growth and invasion into surrounding organs and tissues. Although the etiology is not known fully, pregnancy, estrogen, use of oral contraceptives, trauma and surgical intervention have been proposed as risk factors in sporadic cases. Another characteristic of this tumor which is observed rarely in the normal population is that the prevalence in patients with Polyposis coli syndrome [familial adenomatous polyposis (FAP), Gardner syndrome] is markedly increased compared to the normal population.<sup>7,8,9,10,11,12,13</sup> The prevalence is higher in women and makes a peak in the mid-thirties. However, it may occur in any decade between the ages of 15 and 60 years. On the other hand, there is no clinical marker to predict which patient with PS will develop DT. Nevertheless, it has been shown that the localization of the APC gene mutation which is the most common cause of polyposis coli in the gene codon is associated with development of DT. If the mutation is localized between the codons of 1464 and 1493, the risk of occurrence of DT is increased 20-fold.<sup>14,15</sup>

DT may be localized in the abdominal wall or may have intra-abdominal or extra-abdominal localization. Intra-abdominal DT may be localized in the mesentery, retroperitoneal region and pelvis.<sup>16</sup> When the patients in our series were examined, it was observed that the tumor was most commonly localized in the intra-abdominal region (n=11-74%). This was followed by abdominal wall localization (n=2-13%). In the literature, the most common localizations include intra-abdominal localization and abdominal wall localization. In addition, extra-abdominal involvement (osteoma) accompanied in 4 of our patients (28%) including one in the chin, one in the cranium, one in the vertebra and one in the sacrum.

It has been shown that timing of surgery is also a risk factor in terms of development of DT as well as the type of surgery (total colectomy-protocolectomy) in patients with PS. In the study of Durno et al.,<sup>17</sup> it was shown that the risk was increased 1.8-fold in female patients and in patients who had undergone colectomy at an early age. This risk was not found to be increased in men. Therefore, postponement of the time of colectomy was recommended in female patients with FAP. The fact that the number of the subjects in our series was limited did not allow an adequate evaluation in this issue. However, the number of female patients in our series appears to be high (n=9-65%). When the timing of surgery was examined, it was found that DT developed after colonic surgery in 10 of the subjects and before colonic surgery in 4 subjects (28%).

The clinical course shows variance in DT. Studies have reported that 50% of the cases remain stable, growth and reduction periods occur in 30%, spontaneous regression occurs in 10% and aggressive growth occurs in 10%.<sup>18</sup> Many factors including pregnancy, use of estrogen or use of oral contraceptive, trauma and surgical intervention have been reported to affect this. Growth during pregnancy and in the postpartum period and spontaneous regression during menopause suggest the effect of hormones and hormonal treatment (antiestrogen) is based on these findings.<sup>19</sup>

These tumors are asymptomatic for a long period in many patients, because they frequently grow slowly. Patients become symptomatic when the mass causes compression on visceral organs (intestines, vessels, ureter and nerves) by growing or when the mass invades visceral organs. Patients most commonly present with a clinical picture of abdominal pain, palpable mass, fever and ileus. Computerized tomography which is gold standard is sufficient for the diagnosis. The diagnosis is made easily with this method and the size of the tumor and its relation with the surrounding tissues are demonstrated in detail. Recurrence is also assessed easily with computerized tomography. Other imaging methods (ultrasonography, magnetic resonance or positron emission tomography) may also be utilized according to clinical necessity.<sup>20</sup>

Since the tumor shows a slow and insidious course, most cases are irresectable at the time of diagnosis as in our series. A frequent problem in cases where DT is irresectable is interloop abscesses localized between the intestinal loops. These abscesses cause septic complications which develop secondary to DT. The cause of this has been proposed to be necrosis which develops in the center of the mass and invasion of intestinal wall by the tumor.<sup>21</sup> These patients are followed up with IV antibiotics, if there is no finding of peritonitis; percutaneous drainage is performed, if the clinical picture does not improve with IV antibiotics. It should be kept in mind that symptomatic surgery can be performed, if percutaneous drainage is not appropriate in cases where findings of peritonitis are present and no improvement is obtained with these therapies. In our study, interloop abscess was found in 5 patients (33%). Definitive surgery could not be performed in any of these patients. Percutaneous drainage was performed for 15 times in these 5 patients to achieve palliation.

The treatment method which should be preferred primarily in patients with DT is surgery. Since it is not a capsulated tumor, it cannot be clearly differentiated from the surrounding tissues and it is difficult to be performed R0 resection. This leads to high recurrence rates. In our series, eight of the subjects were inoperable at the time of diagnosis and recurrence was observed in all subjects who

underwent resection. Radiotherapy can be used in addition to surgery or alone. Antiestrogens (tamoxifen, raloxifen), nonsteroidal anti-inflammatory drugs (NSAIDs) (sulindac), tyrosine kinase inhibitors (imatinib, sorafenib), cytotoxic chemotherapeutic agents (doxorubicin, dacarbazine, vinblastine, methotrexate) as systemic treatment agents may be used in cases where a rapid course or recurrence is observed.<sup>22,23,24</sup> Hormonal therapy and NSAIDs may be used as the first option in unresectable and clinically asymptomatic patients because of low toxicity.<sup>25</sup> Cytotoxic chemotherapeutic agents may be preferred especially in symptomatic patients with unresectable and rapidly growing tumors. Tyrosine kinase inhibitors are not indicated in this disease; however, they may be tried in patients in whom all therapeutic agents have been used and the desired response has not been obtained.<sup>26</sup> Nevertheless, an efficient outcome is generally not possible with these therapies.

The fact that most of our patients whom we followed up in our clinic were irresectable and that we had high mortality and recurrence rates and we could not obtain the desired outcomes with radiotherapy and the medical treatment methods mentioned above directed us to new pursuits, because the most common cause of mortality in patients with PS was colorectal cancers until a few decades ago, while prophylactic colectomy before development of colorectal cancer with early diagnosis in these patients causes DT to be the most important cause of mortality in this patient group at the present time. In a study conducted in Cleveland clinic, it was reported that the most common cause of mortality following prophylactic colectomy was DT (about 35% of the subjects) in patients with PS and the mortality related with colorectal cancer remained below 10%.<sup>8</sup> However, wide resections in patients with DT would result in removal of nearly the whole of the intestinal mesentery and nearly total loss of the small bowel. We think that the most appropriate option in these patients for the time being is removal of the whole mesentery. Here, small bowel or multivisceral organ transplantation appears to be an alternative therapeutic method. Multivisceral organ transplantation was performed abroad in one of our patients. After transplantation, this patient was reoperated in our clinic with recurrences (one with intra-abdominal localization and 6 in the abdominal wall) and is still being followed up without any problem in the 3<sup>rd</sup> year after transplantation. Another of our patients is waiting for transplantation in the same clinic. The major disadvantages of this treatment include lack of an experienced center in the area of multivisceral organ transplantation in our country, use of life-long immunosuppression and high cost.

## Conclusion

DTs are mesenchymal tissue tumors which show a local aggressive course without distant metastasis and which have

a high recurrence rate. These tumors which are observed rarely in the general population occur frequently in patients with PS. Currently, DTs are responsible of a great majority of the mortality in patients with PS following prophylactic colectomy. Primary treatment is surgery and total excision of the mass should be targeted. The benefit of non-surgical therapies is limited and still controversial. Half of the patients are inoperable at the time of diagnosis and the recurrence rate is high in the other patients. Therefore, these tumors lead to a high mortality with perforation, hemorrhage and obstructions despite lack of metastasis. The small bowel should be removed with the whole mesentery to obtain the necessary negative surgical border and to prevent development of new DT from the mesentery. In these patients, multivisceral organ transplantation seems to be the best option currently, though it appears to be a complicated intervention.

## Ethics

Ethics Committee Approval: Retrospective study, Informed Consent: Obtained.

Peer-review: External and Internal peer-reviewed.

## Authorship Contributions

Surgical and Medical Practices: Metin Keskin, Emre Balık, Mehmet Türker Bulut, Concept: Metin Keskin, Emre Balık, Mehmet Türker Bulut, Design: Metin Keskin, Emre Balık, Mehmet Türker Bulut, Data Collection or Processing: Ecem Memişoğlu, Adem Bayraktar, Analysis or Interpretation: Muhammed Zübeyr Üçüncü, Metin Keskin, Literature Search: Metin Keskin, Muhammed Zübeyr Üçüncü, Adem Bayraktar, Writing: Metin Keskin, Muhammed Zübeyr Üçüncü, Ecem Memişoğlu.

Conflict of Interest: No conflict of interest was declared by the authors.

Financial Disclosure: The authors declared that this study received no financial support.

## References

1. Bisgaard ML, Fenger K, Bülow S, Niebuhr E, Mohr J. Familial adenomatous polyposis (FAP): Frequency, penetrance and mutation rate. *Hum Mutat* 1994;3:121-125.
2. Church J, Simmang C; Standards Task Force; American Society of Colon and Rectal Surgeons; Collaborative Group of the Americas on Inherited Colorectal Cancer and the Standards Committee of The American Society of Colon and Rectal Surgeons. Practice parameters for the treatment of patients with dominantly inherited colorectal cancer (familial adenomatous polyposis and hereditary non polyposis colorectal cancer) *Dis Colon Rectum* 2003;46:1001-1012.
3. Fletcher CD. Myofibroblastic tumors: an update. *Verh Dtsch Ges Path* 1998;82:75-82.
4. Reitamo JJ, Scheinin TM, Hayry P. The desmoid syndrome. New aspects in the cause, pathogenesis and treatment of the desmoid tumour. *Am J Surg* 1986;151:230-237.

5. Shields CJ, Winter DC, Kirwon WO, Redmond HP. Desmoid tumours. *Eur Surg Oncol* 2001;27:701-706.
6. Bertani E, Chiappa A, Testori A, Mazzarol G, Biffi R, Martella S, Pace U, Soteldo J, Vigna PD, Lembo R, Andreoni B. Desmoid tumors of the anterior abdominal wall: results from a monocentric surgical experience and review of the literature. *Am Surg Oncol* 2009;16:1642-1649.
7. Eigel BA, Zentlor MP and Smith IE. Mesenteric desmoid tumours in Gardner's syndrome-review of medical treatments. *Postgrad Med J* 1989;65:497-501.
8. Belchetz LA, Berk T, Bapat BV, Cohen Z, Gallinger S. Changing causes of mortality in patients with familial adenomatous polyposis. *Dis Colon Rectum* 1996;39:384-387.
9. Merchan NB, Lewiss JJ, Woodruff JM, Leung DH, Brennen MF. Extremity and trunk desmoid tumors:a multifactorial analysis of outcomes. *Cancer* 1999;86:2045-2052.
10. Hosalkar HS, Tarbert JT, Fox EJ, Delaney TF, Abouafia AS, Lackman RD, Musculoskeletal desmoid tumors. *J Am Acad Orthop Surg* 2008;16:188-198.
11. John LP, Shannon CR, Gregory SH, Charles RN. Desmoid tumors of the pelvis and abdominal wall. *J Pel Med and Surg* 2003;9:297-301.
12. Lopez R, Kemolyan N, Moseley HS, Dennis D, Vetto RM. Problems in diagnosis and management of desmoid tumors. *Am Surg* 1990;159:450-453.
13. Lefevre JH, Parc Y, Kernéis S, Goasguen N, Benis M, Parc R, Tiret E. Risk factors for development of desmoid tumours in familial adenomatous polyposis. *Br J Surg* 2008;95:1136-1139.
14. Knudsen AL, Bülow S. Desmoid tumour in familial adenomatous polyposis. A review of literature. *Fam Cancer* 2001;1:111-119.
15. Sturt NJ, Clark SK. Current ideas in desmoid tumors. *Fam Cancer* 2006;5:275-288.
16. Rampone B, Pedrazzoni C, Moralli D, Pinto E, Roviello F. Updates on abdominal desmoid tumors. *World J Gastroenterol* 2007;13:5985-5988.
17. Durmo C, Monga N, Bapat B, Berk T, Cohen Z, Gallinger S. Does early colectomy increase desmoid risk in familial adenomatous polyposis? *Clin Gastroenterol Hepatol* 2007;5:1190-1194.
18. Church JM. Desmoid tumors in patients with familial adenomatous polyposis. *Semin Colon Rectal Surg* 1995;6:29-32.
19. Kasper B, Ströbel P, Hohenberger P. Desmoid tumors : clinical features and treatment options for advanced disease. *Oncologist* 2011;16:682-693.
20. Healy JC, Reznick RH, Clark SK, Phillips RK, Armstrong P. MR Appearances of desmoid tumors in familial adenomatous polyposis. *AJR J Roentgenol* 1997;169:465-472.
21. Bhandari S, Ranchod P, Sinha A, Gupta A, Clark SK, Phillips RK. Familial adenomatous polyposis-related desmoids presenting with air-fluid level: a clinical review and management algorithm. *Dis Colon Rectum* 2012;55:810-814.
22. Patel SR, Benjamin RS. Desmoid tumors respond to chemotherapy; defying the dogma in oncology. *J Clin Oncol* 2006;24:11-12.
23. Monneur A, Chetaille B, Perrot D, Guiromond J, Bertucci F. Dramatic and delayed response to Doxorubicin-dacarbazine chemotherapy of a giant desmoid tumor: case report and literature review. *Case Rep Oncol* 2013;6:127-133.
24. Garbay D, Le Cesne A, Penel N, Chevreau C, Marec-Berard P, Blay JY, Debled M, Isambert N, Thyss A, Bompas E, Collard O, Salas S, Coindre JM, Bui B, Italiano A. Chemotherapy in patients with desmoid tumors: a study from the French Sarcoma Group (FSG). *Ann Oncol* 2012;23:182-186.
25. Kasper B, Ströbel P, Hohenberger P. Desmoid tumors: clinical features and treatment options for advanced disease. *Oncologist* 2011;16:682-693.
26. Heinrich MC, McArthur GA, Demetri GD, Joensuu H, Bono P, Herrmann R, Hirte H, Cresta S, Koslin DB, Corless CL, Dirnhofer S, van Oosterom AT, Nikolova Z, Dimitrijevic S, Fletcher JA. Clinical and molecular studies of the effect of imatinib on advanced aggressive fibromatosis (desmoid tumor). *J Clin Oncol* 2006;24:1195-1203.