

A rare cause of acute abdominal disease: two reports of caecal diverticulum perforation

Fatih Çiftci, M.D.,¹ İbrahim Abdurrahman, M.D.,² Abdülkadir Eren, M.D.³

¹Department of General Surgery, İstanbul Gelişim University Vocational High School of Health Services, İstanbul-Turkey

²Department of Emergency, İstanbul Safa Hospital, İstanbul-Turkey

³Department of Radiology, İstanbul University Cerrahpaşa Faculty of Medicine, İstanbul-Turkey

ABSTRACT

Diverticulum of the caecum is a rare lesion. From a clinical point of view, the inflammation it causes can mimic symptoms of acute appendicitis, causing difficulties in diagnosis and thus prescription of appropriate treatment. It is almost impossible to differentiate this disease from acute appendicitis through physical examination alone, and radiological imaging may also prove insufficient. For this reason, it is common to perioperatively diagnose diverticula of the caecum. Two cases of patients who underwent surgery for perforated caecal diverticula are presently described.

Keywords: Acute abdomen; caecum; diverticulum perforation.

INTRODUCTION

Diverticula of colonic origin are most frequently located on the antimesenteric surface of the sigmoid colon. Incidence of colonic diverticula among the general population is very high. However, diverticula of the right colon and the caecum are comparatively rare. Inflammation of right colon diverticulum generally presents with fever, right lower quadrant pain with evidence of peritoneal irritation, and increase in white blood cell count. Such a presentation would call to mind acute appendicitis. For this reason, definitive diagnosis of the pathology is typically made during surgery. Since 1912, when Potier^[1] first described the disease, many cases of solitary caecal diverticula have been reported. However, a consensus has yet to be reached regarding correct approaches to diagnosis and treatment. Therefore, cases of caecal diverticula must be carefully handled.

Diverticula of the appendix vermiformis are extremely rare and remain asymptomatic until inflammation occurs. Inflamed caecum diverticulum presents with clinical symptoms similar to those of acute appendicitis. Presently described are 2 cases of clinically diagnosed acute appendicitis that were found, during surgery, to be perforated caecal diverticula.

CASE REPORT

Case 1— A 45-year-old woman presented to emergency services complaining of abdominal pain that had begun 2 days prior. On examination, tenderness was present in the right lower quadrant. The patient had experienced neither nausea nor vomiting. White blood cell count was 13400/mm³, and minimal collection was present in the pericecal region on ultrasonography. Computed tomography (CT) scan of the abdomen showed heterogeneity at a site conforming to the lodge of the appendix. The patient was taken to surgery following clinical diagnosis of acute appendicitis. On exploration, however, the appendix vermiformis was found to be intact and the epiploic appendices were found to be oedematous and inflamed. After dissection of the epiploic appendices, perforated diverticulum of the caecum was revealed. Right hemicolectomy and ileocolic anastomosis were then performed. A drain was placed in the lodge and removed on the fourth postoperative day. No complications were observed and the patient was discharged on the seventh day with a prescription for oral ciprofloxacin 7mg/kg twice daily. Pathological examination later revealed diverticular disease

Address for correspondence: Fatih Çiftci, M.D.
Başakşehir Mahallesi, 2. Etap, Erciyes Sok., No: 15/24,
34063 İstanbul, Turkey
Tel: +90 212 - 444 72 32 E-mail: oprdrfatihciftci@gmail.com

Quick Response Code



Ulus Travma Acil Cerrahi Derg
2016;22(3):290–292
doi: 10.5505/tjtes.2015.59879

Copyright 2016
TJTES

of the right colon. Within the first postoperative year the patient developed incisional hernia and underwent a herniorrhaphy. No further complaints were reported during the 3-year follow-up period.

Case 2– A 48-year-old man presented to emergency services complaining of abdominal pain and nausea. White blood cell count was 14700/mm³. Physical examination revealed abdominal wall defense and rebound tenderness in the right lower quadrant. Body temperature was 37.9°C, and no abnormal findings were detected following biochemical examination. Ultrasonography showed increased intensity of the mesenteric tissue in the right lower quadrant. CT scans of the abdomen are shown in Fig. 1.

The patient was taken for laparoscopic exploration with a clinical diagnosis of acute appendicitis or perforated caecal diverticulum. On examination, the appendix vermiformis was found to be intact. However, the caecum and right colon were oedematous and covered with perforated epiploic appendices. Right colon resection and anastomosis were performed. A drain was inserted and removed on the third postoperative day. On the sixth postoperative day, the patient was discharged from the hospital with a prescription for oral cefuroxime axetil 7mg/kg twice daily. Histopathological examination of the tissues showed results similar to those of the previous case. Multiple inflamed diverticula were found, the walls of which included all layers of the colon, and the edges of which included ischemically necrotic areas. The patient reported no complaints associated with the surgery during the 2-year follow-up period.

DISCUSSION

Solitary caecal diverticula are rare lesions that are generally asymptomatic and located on the anterior wall of the caecum.^[2] Contrary to colonic diverticula, caecal diverticula are generally congenital, and their walls include all layers of the colon. Actual prevalence of caecal diverticula is unknown. However, studies have shown that prevalence is higher in Eastern (Asian) populations.^[2,3] Presentation of diverticulitis, a result of occlusion of the diverticular orifice by objects such as fecaloma, mimics that of acute appendicitis. Therefore,

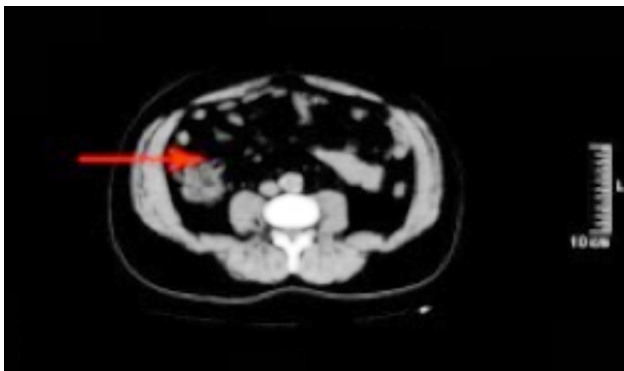


Figure 1. Tomographic view of caecum diverticulum perforation.

clinical differential diagnosis is difficult. Rates of incidence in the literature are based on diagnosis through surgery, and it has been shown that 1 in every 300 cases of acute appendicitis scheduled for surgery is found to be caecal diverticula. Prevalence of caecal diverticula in the general population is thus estimated to be 1/1,000,000.^[3,4]

It has been shown in retrospective studies that, in comparison to sigmoid colon diverticulitis, caecal diverticulitis occurs in relatively young patients (average age: 44 years) and is slightly more common in females.^[3,5,6] One patient presently reported was female, the other male. Attention has been drawn to symptomatic caecal diverticulitis because clinical and laboratory manifestations include leukocytosis in complete blood count, and fever and pain in the right lower quadrant (frequently with defense and rebound tenderness). This presentation, as is to be expected, leads many clinicians to the diagnosis of acute appendicitis. Moreover, imaging techniques are not sufficient for definitive diagnosis. Therefore, patients are frequently taken for surgery with clinical diagnosis of acute appendicitis, as was the case in the present report. In spite of close resemblance to acute appendicitis in clinical, laboratory, and imaging findings, absence of profound anorexia, vomiting, and septic manifestations even 24 hours after abdominal pain onset should lead to the consideration of isolated caecal diverticulitis.^[4,5,7]

If latent perforation due to diverticulitis does develop, the patient may present with a paucity of symptoms and a palpable mass, and postoperatively develop an “onion skin-like” appearance of the region visible on histological examination, which may be limited by fibrin deposits.^[5] In such cases, diseases such as Crohn’s disease, ameboma, tumor of the caecum, gastrointestinal tuberculosis, and pelvic inflammatory disorder, which may present with a palpable mass in the right lower quadrant, should also be considered.^[4,6]

In a study by Chou et al., which included 934 patients who presented with right lower quadrant pain, 91% sensitivity and 99% specificity of ultrasonography for diagnosis was reported.^[8] In another study of right colon diverticular disease, conducted by Sardi et al. and including 881 patients, sensitivity and specificity ratios from CT were reportedly similar to those of ultrasonography.^[9] In the 2 cases presently described, specificity and sensitivity of imaging techniques can be explained by the fact that these cases were not definitively diagnosed as acute appendicitis, as diagnosis of perforations was not possible prior to surgery.

That the 2 large studies mentioned above included all manifestations of right colon diverticula should not be overlooked.^[8,9] However, ultrasonography and CT scanning may not be successful in differentiating caecal diverticular disease, due to the close proximity of the appendix vermiformis, particularly in cases of complicated diverticulitis, which can alter the anatomy of the region. It has been reported that diagnosis

of 65–85% of solitary caecal diverticulitis cases are confirmed during surgery.^[1,4,5,6] This has also been confirmed by the results of the present report.

Conclusion

Acute appendicitis is the most common cause of acute abdominal disease in surgical practice. However, the possibility of caecal diverticulitis and its complications should also be considered in patients presenting with clinical manifestations of acute appendicitis, particularly in patients aged outside the common range for acute appendicitis.

It is suggested that surgeons scheduling patients for acute appendicitis surgery bear in mind the possibility of caecal diverticulitis and are thus prepared for such a finding, in an effort to reduce occurrence of postoperative complication.

Conflict of interest: None declared.

This report was presented as an electronic paper at the 19th National Surgery Congress of Turkey (April 16–20, 2014, Antalya, Turkey).

REFERENCES

1. Connolly D, McGookin RR, Gidwani A, Brown MG. Inflamed solitary caecal diverticulum - it is not appendicitis, what should I do? *Ann R Coll Surg Engl* 2006;88:672–4.
2. Karatepe O, Gulcicek OB, Adas G, Battal M, Ozdenkaya Y, Kurtulus I, et al. Cecal diverticulitis mimicking acute Appendicitis: a report of 4 cases. *World J Emerg Surg* 2008;3:16.
3. Cole M, Ayantunde AA, Payne J. Caecal diverticulitis presenting as acute appendicitis: a case report. *World J Emerg Surg* 2009;4:29.
4. Ruiz-Tovar J, Reguero-Callejas ME, González Palacios F. Inflammation and perforation of a solitary diverticulum of the cecum. A report of 5 cases and literature review. *Rev Esp Enferm Dig* 2006;98:875–80.
5. Kumar S, Fitzmaurice GJ, O'Donnell ME, Brown R. Acute right iliac fossa pain: not always appendicitis or a caecal tumour: two case reports. *Cases J* 2009;2:88.
6. Tihan DN, Küçükyılmaz M, Hepgül G, Öztürk O, Binboğa S. Cecum Diverticulum Perforation Mimicking an Acute Appendicitis: A Report of Two Cases. *Kolon Rektum Hast Derg* 2011;21:126–9.
7. Abogunrin FA, Arya N, Somerville JE, Refsum S. Solitary caecal diverticulitis-a rare cause of right iliac fossa pain. *Ulster Med J* 2005;74:132–3.
8. Chou YH, Chiou HJ, Tiu CM, Chen JD, Hsu CC, Lee CH, et al. Sonography of acute right side colonic diverticulitis. *Am J Surg* 2001;181:122–7.
9. Sardi A, Gokli A, Singer JA. Diverticular disease of the cecum and ascending colon. A review of 881 cases. *Am Surg* 1987;53:41–5.

OLGU SUNUMU - ÖZET

Nadir akut karın nedeni: Çekum divertikül perforasyonu (İki olgu)

Dr. Fatih Çiftci,¹ Dr. İbrahim Abdurrahman,² Dr. Abdülkadir Eren³

¹İstanbul Gelişim Üniversitesi, Sağlık Hizmetleri Meslek Yüksekokulu, Genel Cerrahi Anabilim Dalı, İstanbul, Türkiye

²İstanbul Safa Hastanesi, Acil Tıp Kliniği, İstanbul

³İstanbul Üniversitesi Cerrahpaşa Tıp Fakültesi, Radioloji Anabilim Dalı, İstanbul

Çekum divertikülü nadir görülen bir lezyon olmakla birlikte, klinik semptomları akut apandisit ile benzerlik gösterdiğinden dolayı tanı ve tedavi açısından zorluklar sergiler. Fiziksel inceleme ile akut apandisitinden hemen hemen hiçbir zaman ayırt edilemez. Radyolojik görüntüleme yetersiz kalabilir. Bu nedenle tanının ameliyat esnasında konulduğu durumlar olur. Bu yazıda, perforasyonlu çekum divertikülü saptanıp ameliyat edilen iki olgu sunuldu.

Anahtar sözcükler: Akut karın; çekum; divertikül perforasyonu.

Ulus Travma Acil Cerrahi Derg 2016;22(3):290–292 doi: 10.5505/tjtes.2015.59879