

A stereological study on determination of ventricular wall volume of the heart in female and male quails

Gamze Çakmak¹, Hüseyin Karadağ², Zafer Soygüder¹, Murat Çetin Rağbetli³, Mikail Kara⁴, Veysel Akyol⁵

¹Department of Anatomy, Faculty of Veterinary Medicine, University of Van Yuzuncu Yil, Van, Türkiye.

²Faculty of Dentistry, Dentistry University of Istanbul Gelisim, Istanbul, Türkiye

³Department of Histology and Embryology, Faculty of Medicine, University of Karamanoğlu Mehmetbey, Karaman, Türkiye

⁴Department of Histology and Embryology, Faculty of Medicine, University of Mustafa Kemal, Hatay, Türkiye

⁵Department of Nursing Fundamentals, Faculty of Health Sciences, University of Van Yuzuncu Yil, Van, Türkiye

Key Words:

heart
stereology
ventricle
volume
quail

Received : 04.03.2022
Accepted : 10.01.2023
Published Online : 30.04.2023
Article Code : 1082796

Correspondence:

G. ÇAKMAK
(vetgamze@hotmail.com)

ORCID

G. ÇAKMAK : 0000-0002-3970-3040
H. KARADAĞ : 0000-0002-0174-6504
Z. SOYGÜDER : 0000-0002-0489-5062
MÇ. RAĞBETLİ : 0000-0002-8189-264X
M. KARA : 0000-0002-2789-1849
V. AKYOL : 0000-0002-6355-441X

This study was presented as an oral presentation at the congress prepared by Selçuk University on date 27-28-29 October 2011 at the 7th National Veterinary Anatomy Congress. The congress was held in Antalya.

ABSTRACT

In this study, ventricular wall volume of female and male quails was investigated stereologically. Six females and six males quails were used in this study. All of the animals were perfused. After the perfusion, the quails were kept in 10% formaldehyde solution. Afterwards, chests of quails were cut and their hearts were resected. Ventricles of the hearts were separated. Specific ratio of tissue samples was obtained from each ventricle. The 5- μ m thick samples were cut by using a microtome. Sequentially, 10 sections were obtained. These sections were stained by hematoxylin eosin and photographed. Volumes of wall of the ventricles were estimated by using the Cavalieri's Principle. In this study, the volume values of ventricular walls of female and male quails were compared. Some differences were found between these values. The volume values of ventricular walls of six female quails were compared with each other. While the lowest volume value was 0.398 cm³, the highest volume value was 0.612 cm³. The volume values of the male quails were between 0.438 cm³-0.817 cm³. It was found that volume values of ventricular walls of male quails were higher than volume values of ventricular walls of female quails. As a result, although there was a specific distinction between volume values of ventricular walls of female and male quails. There was no difference between statistic values (P>0.05). It was thought that this study will be guiding for other related studies.

INTRODUCTION

In birds, the circulatory system carries oxygen, nutrients and hormones necessary for the continuation of life, and ensures that the wastes of metabolism and carbon dioxide are expelled from the cells (Dursun, 2002). The heart, the center of the circulatory system, is a hollow muscular organ (Dursun, 1994). Although the position of the heart varies according to the animal species, it is surrounded by the pericardium in the caudoventral direction in the cranial region of the thoracoabdominal cavity in birds (Dursun, 2002). In birds, the heart consists of the right atrium, left atrium, right ventricle and left ventricle, as in mammals (Dursun, 1994; Dursun, 2002). The right ventricle reaches only 2/3 of the heart, and the apex of the heart is formed by the left ventricle. It has been noted that the left ventricle is thick-walled and cone-shaped and appears circular in cross-section. (Dursun, 2002). Various studies have been conducted to accurately and clearly determine the volume of the heart. Many studies on experimental animals and humans have revealed right ventricular and left ventricular volumes by various methods (Mahoney et al., 1987; Aebischer and Czedledy, 1989; Eishstacdt et al., 1992; Heusch, 1999; Cui et al., 2004). Methods that can be used to monitor the heart

ventricles and calculate their volume are used in the diagnosis and treatment of heart diseases. It has been suggested that some heart diseases may lead to deformations in the ventricles and deviations in the ventricular volume (Noerdegraaf et al., 1997). In a study conducted on Kivircik sheep and hair goats, the volumes of right ventricle side wall, left ventricle side wall, right ventricle cavity, left ventricle cavity and interventricular septum were calculated (Ince and Kahvecioglu, 2010). In another study on dogs, measurements obtained with the principle of fluid displacement in calculating the volume of the right ventricle were compared with echocardiographic measurements and a positive ratio was found between them (Aebischer and Czedledy, 1989). The volume values were calculated using balloons placed in the heart cavities by another method (Sapin et al., 1993; Siu et al., 1993). It was determined that the methods used to evaluate the heart volume were not sufficient to preserve the anatomical structure of the heart.

The volumes of objects with regular or symmetrical shapes are calculated using the following mathematical formula; $V=t \times a$. In this equation, V is the volume, t is the height of the object, and a is the base area of the object (Sahin et al., 2003a; Sahin et al., 2003b). The Cavalieri's Principle is used to

calculate the volumes of objects with an irregular shape (Odaci et al., 2003). To calculate the volume ratio, the formula $V_v(Y.ref) = P_p(Y.ref) = P(Y)/P(ref)$ is used according to the Cavalieri Principle (Howard and Reed, 1998).

It is known that it is possible to obtain the most accurate quantitative analyzes with stereological methods used to calculate the volumes of three-dimensional objects (Howard and Reed, 1998; Glaser and Glaser, 2000; Bertram, 2001; Odaci et al., 2003; Sahin et al., 2003a; Sahin et al., 2003b).

Recently, a special importance has been given to poultry farming in Türkiye. Considering this importance, it is aimed to calculate the volume of a quail heart. It is believed that this study will shed light on all morphological and anatomical studies on the heart of birds, as well as stereological studies.

MATERIAL and METHODS

Animals

In this study, 6 adult female healthy quails and 6 adult male healthy quail (*Coturnix coturnix japonica*) two months old and weighing 180 ± 5 g were used. 10% buffered formaldehyde solution was applied by intracardiac perfusion technique (Romeis, 2001). The quails anesthetized with ketamine hydrochloride (50mg/kg i.m) injection were kept in 10% formaldehyde solution pool for one week (Aslanbey et al., 1987).

Resection of the heart

The chest cavity of quails was opened at the level of the sternum to resect their hearts. The heart, aorta, and pulmonary vein were resected in the thoracic cavity.

Sampling type

Before starting the study, a pilot study was specifically planned. With this planned pilot study, it was aimed to determine the number of animals, the number of sections and sampling to be used in the study. Studies have shown that in a stereological study at least five animals in a group must be used to achieve an error coefficient of approximately 0.05 (Weibel, 1980; Cruz- Orive and Weibel, 1990). Calculation of the error coefficient was based on the square root of the total variant/total number of points. For this cross-check method, it was determined that the number of individuals in the sample group was sufficient by using the SHTEREOM I package program (Gundersen and Jensen, 1987).

Five quails were used for the pilot study. Tissues were dissected and embedded in paraffin after tissue follow-up. Random 5 μ m thick transversal sections were taken from the quail hearts using a Rotary microtome (Leica RM 2135, Nussloch, Germany) from the beginning of the tissue to the end and transferred to slides after the procedure. After the sections were deparaffinized, they were stained with hematoxylin-eosin and covered with a lamella (Luna, 1968) (Figures 1, 2, 3, 4). The sections were sampled at the ratio of 1/40 as 8-10 sections for each animal. Systematic random sampling was preferred, and any sections after the first 40 sections were taken and the next 40 sections continued to be taken. It was determined that

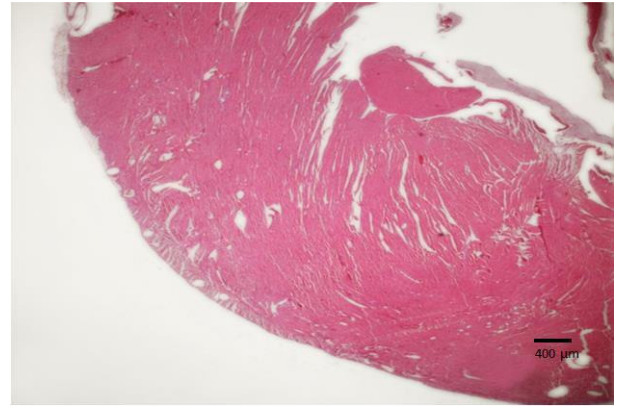


Figure 1. The ventricular wall of the quail X1.25 magnification (Hematoxylin eosin).

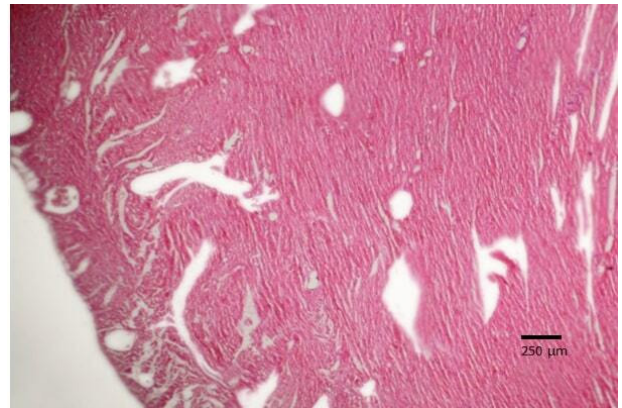


Figure 2. The ventricular wall of the quail X4 magnification (Hematoxylin eosin).

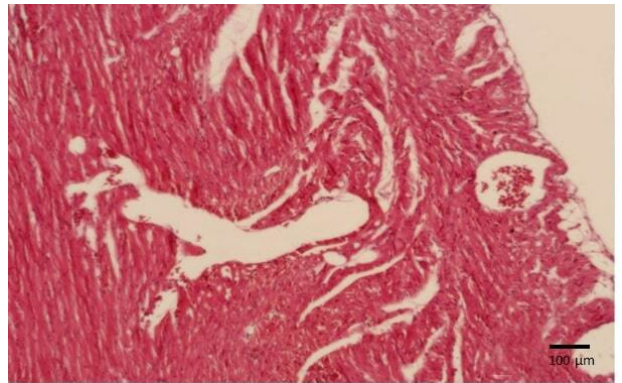


Figure 3. The ventricular wall of the quail X10 magnification (Hematoxylin eosin).

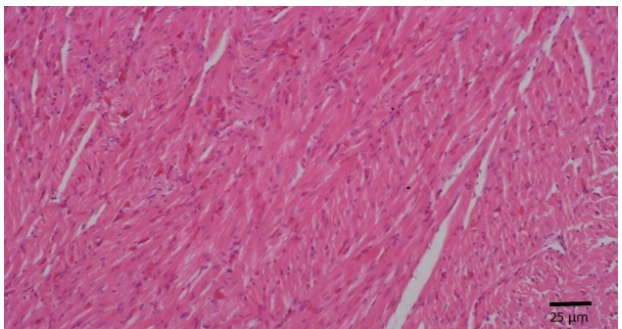


Figure 4. The ventricular wall of the quail X40 magnification (Hematoxylin eosin).

10 sections should be taken according to the values obtained from the pilot study. The study was carried out according to the values determined in the pilot study.

Image Analysis

Because of the quail heart has a medium-sized structure, stereological stepping was necessary. Images were obtained with objective x10 magnification using a motorized table with stereological stepping method. Approximately 30-35 images were obtained for each section. Using the point grid, the area was calculated at objective x10 magnification, and then the volume was calculated. SHTEREOM I package program was used for this process. The calculation basis of the program is based on the Cavalieri's Principle (Odaci et al., 2003). The entire ventricular volume of the heart was determined as a whole. Right ventricular and left ventricular volumes and spaces were also counted. Only the ventricular wall volume was calculated, since results close to the truth could not be obtained. This is because the shrinkage rate cannot be calculated precisely and accurately due to the water lost during tissue processing and other processes.

Calculation was made with the number of points because the numerical ratio of the points is considered valid instead of

was taken as a basis.

Volume of the ventricular wall = volume rate × reference volume of the ventricular wall

Reference volume of ventricular wall = distance of the section range × real area of the point × number of points

The ventricular wall volume of the heart was measured according to Archimedes' fluid displacement principle. 10 ml of distilled water was placed in the graduated cylinder. After the hearts were thrown into the water in the graduated cylinder, the amount of water they overflowed was calculated. The volume values of the ventricular wall of male and female quails were obtained according to Archimedes' fluid displacement principle.

RESULTS

The ventricular wall total volume values of six quails in the same age group from female animals were B1=0.516 cm³, B2=0.589 cm³, B3=0.556 cm³, B4=0.485 cm³, B5=0.398 cm³ and B6=0.612 cm³, respectively. from the first to the last. In this study, the highest volume value among female animals was calculated as 0.612 cm³ (Table 1) (Figure 5).

Table 1. The volume values of ventricular wall of quails (Q) (cm³).

Quail (Q)	Female	Male
Q1	0.516	0.438
Q2	0.589	0.617
Q3	0.556	0.598
Q4	0.485	0.817
Q5	0.398	0.590
Q6	0.612	0.610
Means	0.526	0.611

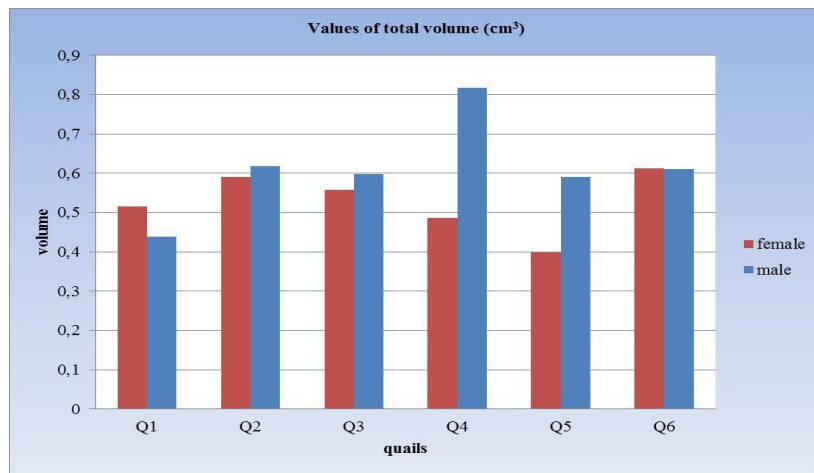


Figure 5. The total volume values of ventricular wall in male and female quails.

the volume in volume calculations (Howard and Reed, 1998; Howard and Reed, 2005). In order to avoid unnecessary point counts in all tissues, counting the points at regular intervals

The ventricular wall total volume values of male quails in the same age group were calculated as B1=0.438 cm³, B2=0.617 cm³, B3=0.598 cm³, B4=0.817 cm³, B5=0.590 cm³ and

B6=0.610 cm³. In the evaluation made among male animals, it was seen that the highest volume value belonged to the B4 coded animal. The highest value following this was observed as 0.81 cm³. Although the volume values in male animals seem close to each other, the difference between the values was not remarkable since there was no statistical difference. When the volume values of male and female animals were compared, it was seen that the ventricular wall volume values were higher in favor of male quails (Table 1) (Figure 5). While the coefficient of error (CE) value obtained in the study was 0.04 in female quails, it was 0.037 in male quails. In this case, since the error rate coefficient CE<0.05 is a reasonable value, it has been determined that the results are reliable (Table 2).

quails was 725 points. In male quails, this value was found to vary between 604 points and 1126 points. It was determined that the average number of points per area in male quails was 843 points (Table 3). It was noted that the average number of points per area in male quails was higher than in female quails. Obtaining these values was an important result for the present study.

Based on Archimedes' principle of fluid displacement, the volume of the ventricular wall of the heart was measured. The ventricles were thrown into the water as a whole according to the Archimedes' principle. The ventricular cavity was also included in the calculation of the volume values of the

Table 2. The values of Coefficient of Error (CE)

Quail (Q)	Female	Male
Q1	0.0424	0.0422
Q2	0.0366	0.0369
Q3	0.0371	0.0364
Q4	0.0449	0.0366
Q5	0.0451	0.0371
Q6	0.0366	0.0378
Means	0.0408	0.0378

Table 3. The number of points per area (Noise (N)).

Quail (Q)	Female	Male
Q1	711	604
Q2	812	851
Q3	767	824
Q4	669	1126
Q5	549	814
Q6	844	841
Means	725	843

Table 4. The volume values of ventricular wall of quails by Archimed Principle and stereological method.

Quail (Q)	Female		Male	
	Archimedes (ml)	Stereological (cm ³)	Archimedes (ml)	Stereological (cm ³)
Q1	1.5	0.516	2.0	0.438
Q2	1.0	0.589	2.0	0.617
Q3	1.0	0.556	1.5	0.598
Q4	1.5	0.485	1.0	0.817
Q5	0.5	0.398	1.5	0.590
Q6	1.5	0.612	2.0	0.610

Based on the number of points per area, it was observed that this value varied between 549 points and 844 points in female quails. The average number of points per area in female

ventricles thrown into the water. Unlike Archimedes' principle, only the volume of the ventricular wall was calculated using the stereological method. The volume of the ventricular cavity

was not included in the measurement in the stereological study. Therefore, a difference was determined between the volume values, which were obtained by the stereological methods, and the volume values, which were obtained by the Archimedes' principle (Table 4). After the ventricles were placed in water, their values and the difference between them were obtained.

Statistical Analysis

SPSS (SPSS for Windows) package program was used in the statistical analysis of the data. First of all, normality test was performed to determine whether the data were normally distributed. According to the normality test, it was determined that the data were normally distributed with 95% confidence. Then, independent samples t-test was performed to reveal the difference between genders. As a result, there was no statistically significant difference between the genders in terms of total volume values ($P > 0.05$). In addition, it was determined that male animals were only numerically higher than the total volume values of female animals (Table 5).

created and actual measurements are made on these hearts (Heusch et al., 1999; Cui et al., 2004).

In this study, the ventricular volume of the heart was measured based on Archimedes' fluid displacement principle. In this method, the ventricle wall of the heart was considered as a whole and the ventricles obtained from quails were placed separately in a graduated cylinder filled with distilled water. Then the amount of water remaining in the graduated cylinder was measured. In this way, it was thought that the volume values of the ventricle wall of the heart are very subjective values for us and that there may be errors in the calculations due to the irregular structure of the heart. Thus, as a result of the study, stereological measurement values were taken as basis..

In the study on the stereological evaluation of the heart ventricle in Kivircik sheep and hair goats, the volume of the left ventricle, the right ventricle and the interventricular septum and the volume of the ventricular cavity were calculated (Ince

Table 5. Statistical analysis.

Total Volume Statistics			
Sex	Number of Animals	Mean±Std. Deviation	Significant Value
Male	6	0.612260±0.120821466	0.175
Female	6	0.526592±0.078058562	

DISCUSSION

Although different volume calculation techniques are used in scientific research, it is discussed whether these techniques have superiority to each other (Gundersen, 1986; Gundersen and Jensen, 1987; Howard and Reed, 1998). By means of the stereological methods that provide data and interpretations regarding the real three-dimensional structural properties of two-dimensional cross-section images obtained from histological materials by various methods; morphometric values such as volume, surface area, number and length can be obtained (Weibel, 1980; Unal et al., 2002).

In other words, new approaches called stereological methods are widely used in the morphometric evaluation of biological structures (Gundersen, 1986; Gundersen and Jensen, 1987; Howard and Reed, 1998; Gevrek, 2011). Both the use of systematic random sampling method and the use of certain formulas with proven mathematical values that evaluate the scientific structure increase reliability (Mayhew and Gundersen, 1996; Cruz- Orive, 1997). When a biological construct is analyzed by stereological methods, there is no hesitation about the results (Cruz- Orive and Weibel, 1990).

In many studies, the method used to evaluate the ventricular wall volume and the actual measurement values obtained directly from the heart are needed to determine the accuracy of the measurement values. Thus, either the Archimedes' principle (Lipton et al., 1978) or samples of each heart are

and Kahvecioglu, 2010). However, in this study, it was aimed to calculate the whole ventricular wall volume in quails. The study differs in terms of regions calculated with the study of Ince and Kahvecioglu. In addition, the volume values of the right ventricle and left ventricular cavities were not calculated in this study.

In another study, the effects of prenatally administered diclofenac sodium on the heart tissue of postnatal rats were investigated by stereological and histological methods using the Cavalieri principle (Gevrek, 2011). When the results of this study were evaluated, it was seen that diclofenac sodium given at a dose of 1 mg/kg before birth affected the development of the heart. Although there are similarities in stereological methods and volume calculation methods between this study on the heart of rats and our study, they differ with drug administration.

CONCLUSION

In the present study, the Cavalieri's principle was used to calculate the volume of ventricular walls in the hearts obtained from male and female quails. This study was planned due to the limited number of studies on the morphometry of the heart in birds and the lack of a stereological study on the calculation of the ventricular wall volume values. It was thought that this study would both contribute to the literature and shed light on future studies on anatomy, morphology, and histology of heart as well as stereological studies. Furthermore, it was hoped that

this stereological study will be the basis for the studies on different birds and various systems.

DECLARATIONS

Ethics Approval

Final report of the research project was approved by Van Yuzuncu Yil University Animal Researches. Local Ethical Committee in the session held on 28/06/2018 decision number 2108/06

Conflict of Interest

There is no conflict of interest between authors.

Consent for Publication

Publication permission approved by all authors

Author contribution

Idea, concept and design: G.Ç

Data collection and analysis: G.Ç, H.K., M.Ç.R., M.K., V.A.

Drafting of the manuscript: G.Ç, H.K, Z. S, M.Ç.R.

Critical review: G.Ç, H.K, Z. S, M.Ç.R

Data Availability

Data supporting the findings of this study are available from the corresponding author upon reasonable request.

Funding

There is no funding for this study.

Acknowledgements

We want to thank to dear Prof. Dr. Murat Çetin RAGBETLİ the head of department of Histology-Embryology in Medicine Faculty, Van Yuzuncu Yil University

REFERENCES

1. Aebischer, N. M., & Czegledy, F. (1989). Determination of right ventricular volume by two-dimensional echocardiography with a crescentic model. *Journal American Society Echocardiography*, 2(2), 110-8. [https://doi.org/10.1016/S0894-7317\(89\)80073-2](https://doi.org/10.1016/S0894-7317(89)80073-2)
2. Aslanbey, D., Saglam, M., Gurkan, M., & Olcay, B. (1987). Kanatlılarda ketalar ile genel anestezi. *Ankara Universitesi Veteriner Fakültesi Dergisi*, 34(2), 288-299. https://doi.org/10.1501/Vetfak_0000001081
3. Bertram, J. F. (2001). Counting in the kidney. *Kidney International*, 59, 792-6. <https://doi.org/10.1046/j.1523-1755.2001.059002792.x>
4. Cruz-Orive, L. M. (1997). Stereology of single objects. *Journal of Microscopy*, 186, 93-107. <https://doi.org/10.1046/j.1365-2818.1997.1380695.x>
5. Cruz-Orive, L. M. & Weibel, E. R. (1990). Recent stereological methods for cell biology: a brief survey. *Lung Cellular and Molecular Physiology. American Journal of Physiology*, 258(4), 148-156. <https://doi.org/10.1152/ajplung.1990.258.4.L148>

6. Cui, W., Anno, H., Kondo, T., Guo, Y., Sato, T., Sarai, M., Shinozaki, H., Kakizawa, S., Sugiura, K., Oshima, K., Katada, K., & Hishida, H. (2004). Right ventricular volume measurement with single-plane Simpson's method based on a new half-circle model. *International Journal of Cardiology*; 94(2-3), 289-292. <https://doi.org/10.1016/j.ijcard.2003.06.003>
7. Dursun, N. (1994). *Veterinary Anatomy II* (2nd ed.) Medisan Publishing.
8. Dursun, N. (2002). *Anatomy of Domestic Birds*. Medisan Publishing.
9. Eishstaedt, H., Danne, O., Schroeder, R. J., & Kreuz, D. (1992) Left ventricular hypertrophy regression during antihypertensive treatment. *The Journal of Clinical Investigation*; 70, 79-86. <https://doi.org/10.1007/BF00207616>
10. Gevrek F. (2011). Investigation of the effects of prenatally administered diclofenac sodium on heart tissue in postnatal rats by histological and stereological methods.. University of Yuzuncu Yil, Faculty of Medicine. Doctorate Thesis; Van.
11. Glaser, J. R., & Glaser, E. M. (2000). Stereology, morphometry and mapping: the whole is greater than the sum of its parts. *Journal of Chemical Neuroanatomy*; 20(1),115-126. [https://doi.org/10.1016/S0891-0618\(00\)00073-9](https://doi.org/10.1016/S0891-0618(00)00073-9)
12. Gundersen, H. J. G. & Jensen, E. B. (1987). The efficiency of systematic sampling in stereology and its prediction. *Journal of Microscopy*, 147:229-263. <https://doi.org/10.1111/j.1365-2818.1987.tb02837.x>
13. Gundersen, H. J. G. (1986). Stereology of arbitrary particles. A review of unbiased number and size estimator and presentation of some new ones in memory of William R Thomson. *Journal of Microscopy*, 143(1), 3-45.
14. Heusch, A, Koch, J. H., Kragmann, O. N., Korbmacher, B., & Bourgeois, M. (1999). Volumetric analysis of the right and left ventricle in a porcine heart model: comparison of the three-dimensional echocardiography magnetic resonance imaging and angiocardigraphy. *European Journal of Ultrasound*; 9(3), 245-255. [https://doi.org/10.1016/s0929-8266\(99\)00032-4](https://doi.org/10.1016/s0929-8266(99)00032-4)
15. Howard, C. V., & Reed, M. G. (2005). Three-dimensional measurement in microscopy. In: Cruz-Orive LM, editor. *Unbiased Stereology*, (2nd ed.). Taylor & Francis.
16. Howard, C. V., & Reed, M. G.. (1998). *Unbiased Stereology: Three-dimensional measurement in microscopy* (1st ed.) UK: BIOS Scientific Publishers.
17. Ince, N., & Kahvecioglu, O. (2010). Examination of ventriculi cordis by stereologic method in sheep (kivircik sheep) and goats (hair goat) *Journal of Faculty of Veterinary Medicine of Istanbul University*; 36(1), 21-37.
18. Lipton, M. J., Hayashi, T. T., Boyd, D., & Carlsson, E. (1978). Measurement of left ventricular cast volume by computed tomography. *Radiology*, 127(2), 419-423. <https://doi.org/10.1148/radiology.127.2.419>

doi.org/10.1148/127.2.419

19. Luna, L. G. Manual of histologic staining methods of the armed forces institute of pathology, (3rd ed.) McGraw-Hill Book Company

20. Mahoney, L. T., Smith, W., Noel, M. P., Florentine, M., Skorton, D. J., & Collins, S. M. (1987). Measurement of right ventricular volume using cine computed tomography. *Investigation Radiology*; 22(6), 451-5. <https://doi.org/10.1097/00004424-198706000-00001>

21. Mayhew, T. M., & Gundersen, H. J. G. (1996). If you assume, you can make an ass out of u and me': a decade of disector for stereological counting of particles in 3D space. *Journal of Anatomy*, 188, 1-15.

22. Noerdegraaf A. V., Marcus, J. T., Roseboom, B., Postmus, P. E., Faes, T. J., & de Vries P. M. (1997). The effect of right ventricular ejection fraction in pulmonary emphysema. *Chest*, 112 (3), 640-5. <https://doi.org/10.1378/chest.112.3.640>.

23. Odaci, E., Sahin, B., Sonmez, O. F., Kaplan, S., Bas, O., Bilgic, S., Bek, Y., & Ergur, H. (2003). Rapid estimation of the vertebral body volume. A combination of the Cavalieri Principle and computed tomography images. *European Journal of Radiology*, 48(3), 316-26. [https://doi.org/10.1016/s0720-048x\(03\)00077-9](https://doi.org/10.1016/s0720-048x(03)00077-9)

24. Romeis, B. (1948). *Mikroskopische technik*. R. Oldenburg.

25. Sahin, B., Alper, T., Kokcu, A., Malatyalioglu, E., & Kosif, R. (2003a). Estimation of the amniotic fluid volume using Cavalieri method on ultrasound images. *International Journal of Gynecology & Obstetrics*, 82, 25-30. [https://doi.org/10.1016/s0020-7292\(03\)00122-x](https://doi.org/10.1016/s0020-7292(03)00122-x)

26. Sahin, B., Emirzeoglu, M., Uzun, A., Incesu, L., Bek, Y., Bilgic, S., & Kaplan S. (2003b). Unbiased estimation of the liver volume by the Cavalieri Principle using magnetic resonance images. *European Journal of Radiology*; 47(2), 164-7. [https://doi.org/10.1016/s0720-048x\(02\)00152-3](https://doi.org/10.1016/s0720-048x(02)00152-3)

27. Sapin, P. M., Schroeder, K. M., Smith, M. D., DeMaria, A. N., & King, D. L. (1993). Three dimensional echocardiographic measurement of left ventricular volume in vitro: comparison with two dimensional echocardiography and cine ventriculography. *Journals of the American College of Cardiology*, 22, 1530-7. [https://doi.org/10.1016/0735-1097\(93\)90567-K](https://doi.org/10.1016/0735-1097(93)90567-K)

28. Siu, S. C., Rivera, M., Guererro J., Handschumacher, M. D., Lethor, J., Weyman, A. E., Levine, R. A., & Picard, M. H. (1993). Three dimensional echocardiography: in vivo validation for left ventricular volume and function. *Circulation*, 88(1), 1713-5. <https://doi.org/10.1161/01.cir.88.4.1715>

29. Unal, B., Aslan, H., Canan, S., Sahin, B., & Kaplan, S. (2002). Important error sources and solution suggestions of old (biased) methods used when counting objects in biological environments. *Journal of Medical Science*, 22 1-6.

30. Weibel, E. R. (1980). *Stereological Methods*. Vol 2: *Theoretical Foundations*. Academic Press Inc.