

See discussions, stats, and author profiles for this publication at: <https://www.researchgate.net/publication/328402904>

Ileocecal invagination due to an inflammatory fibroid polyp. A case report

Article in *Annali italiani di chirurgia* · October 2018

CITATIONS
0

READS
20

3 authors, including:



Uğur Ekici
Gelisim Üniversitesi

27 PUBLICATIONS 9 CITATIONS

[SEE PROFILE](#)



Serhan Yilmaz

3 PUBLICATIONS 1 CITATION

[SEE PROFILE](#)

Some of the authors of this publication are also working on these related projects:



Knowing these rates can help the surgeon in early surgical intervention, so the possible complications of perforated appendicitis might be decreased via early surgical intervention. [View project](#)

Ileocecal invagination due to an inflammatory fibroid polyp.

A case report



Ann Ital Chir, Digital Edition 2018, 7
pii: 0000000000000 - Epub, Jan. 16
free reading: www.annitalchir.com

Uğur Ekici*/**, Serhan Yılmaz**/***, Faik Tatlı****

*Gelisim University, Scholl of Health Sciences, Health Administration Department, Istanbul, Turkey

**Special Esencan Hospital, General Surgery Department, Istanbul, Turkey

***Esenyurt University, Vocational Collage, Istanbul, Turkey

****Harran University, General Surgery Department, Sanliurfa, Turkey

Ileocecal invagination due to an inflammatory fibroid polyp. A case report

The invagination develops as a result of the dislocation of proximal bowel segment within the following distal portion. It is rarely seen in adult population. It generally develops as a result of intestinal wall neoplasia in the adult patients. Only 3-6% of gastrointestinal system tumors are seen to be localized to small bowels. Inflammatory fibroid polyp is a rarely seen benign tumor in gastrointestinal system. We present the case of 47 year-old female with ileo-cecal invagination caused by Inflammatory fibroid polyp in ileum.

KEY WORDS: Invagination, Intusseption, Inflamaotry Fibroid Polyp

Introduction

The invagination develops as a result of the dislocation of proximal bowel segment within the following distal portion. Even though it is a common acute abdomen factor that is seen among pediatric patient group, it is rarely seen in adult population ¹. In the adult population, it generally develops as a result of dislocation of the appendix of intestinal wall neoplasia within the lumen during the peristalsis ². Being one of these lesions, the inflammatory fibroid polyp (IFP) is a rarely seen benign tumor most frequently involving the gut and small bowel in gastrointestinal system (GIS) ³⁻⁴. It originates from the submucosa. Trauma, allergy, bacterial infection, and chemical and physical agents might play role in its etiology ⁵. In the present study, an IFP case leading to invagination is discussed.

Case Report

47 year-old female patient having no comorbid disease or previous abdomen surgery history applied to our emergency service with the complaints of abdominal pain for 1 week and vomiting and nausea for 2 days. There was no fecal discharge for 2 days. In abdominal examination, the distention, decrease in intestinal voice, and sensitivity throughout the abdomen were detected. In rectal examination, the rectum was empty and there is no indicator of intestinal hemorrhage. Hematocrit was 28.1, hemoglobin was 9.1, and white blood cell count was 14.8. The serum electrolyte level was normal. In direct abdominal radiograph taken in standing position, a liquid-air leveling localized to right lower quadrant was seen (Fig. 1A). In contrasted abdominal tomography (CT), ileocecal invagination was observed in approximately 8cm segment of right lower quadrant, and the jejunal anses were dilated in proximal (Fig. 1B). Taken into surgery with these findings, the patient was found to have approx. 10 cm ileum segment (starting from the ileocecal valve) invaginated into the cecum. There was no circulatory impairment. When the bowel was re-invaginated, a 3cm x 5cm intralumen mass was observed at approx. 10cm proximal to the ileocecal valve

Pervenut in Redazione Ottobre 2017. Accettato per la pubblicazione Maggio 2018

Correspondence to: Uğur Ekici, Gelisim Universitesi Sağlık Bilimleri Yüksek Okulu, Cihangir, J. Kom. Er Hakan Öner Sk. No:1, 34310 Avcılar, Istanbul, Turkey (e-mail: opdrugurekici@hotmail.com)

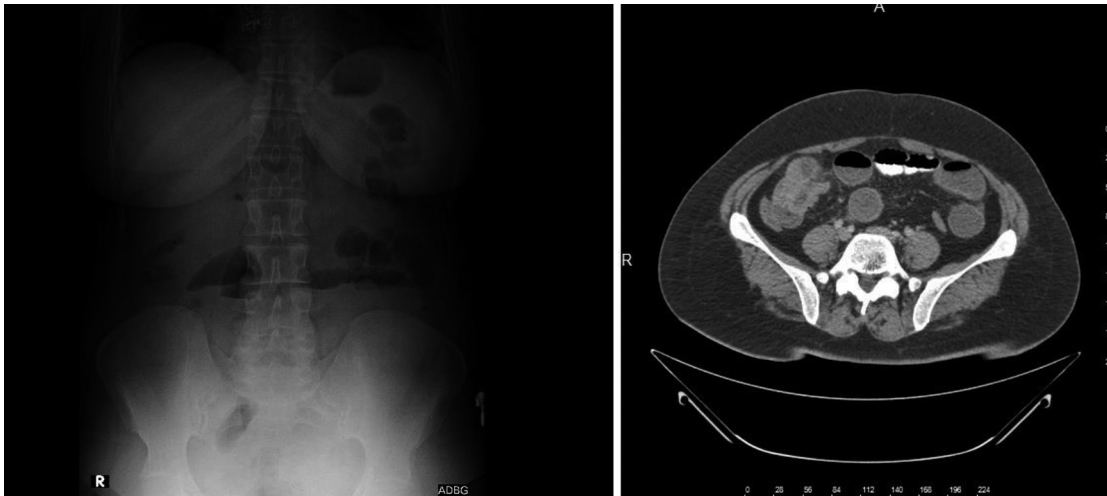

Fig. 1

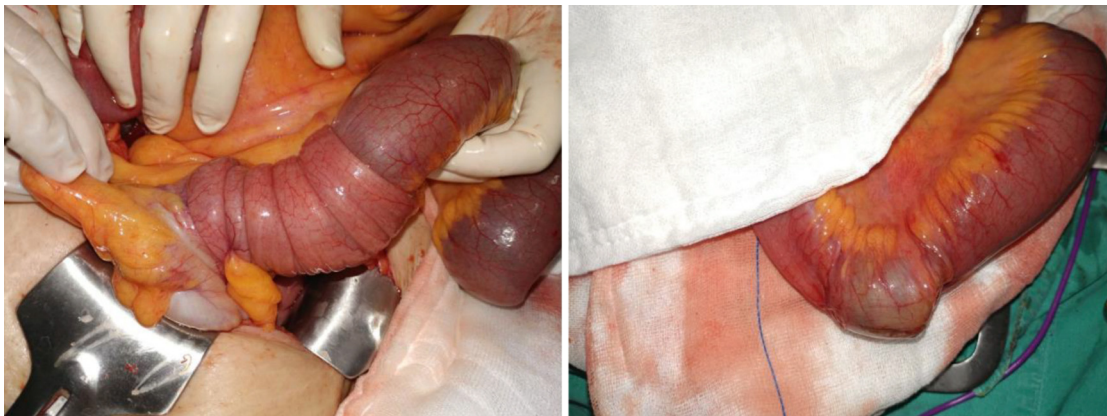


Fig. 2

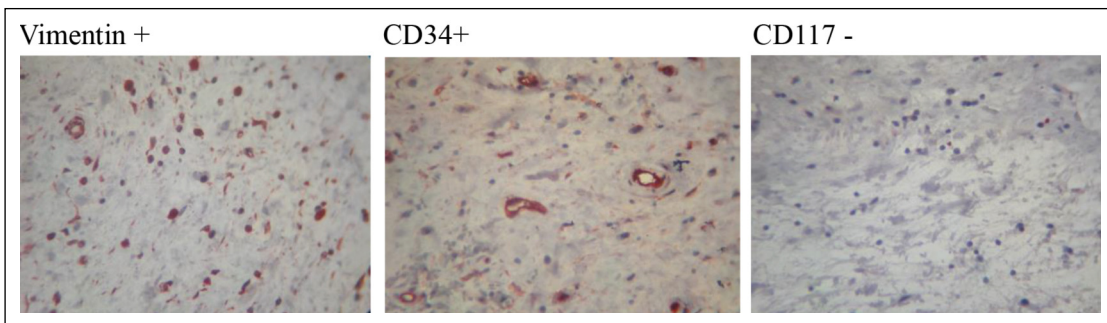


Fig. 3

(Fig. 2). The patient was undergone right hemicolectomy and extreme collateral ileotransversostomy with terminal ileum resection. The patient was discharged on 4th postoperative day, and kept in follow-up period for 3 months. No complication was observed since then. In histopathological analysis, the mixed-type inflammatory cell infiltration rich in eosinophil leucocytes and the veins were observed in tissues of small bowels. In immune staining, Vimentin and CD34 were found to be positive, whereas CD117 (C-K T) was found to be negative. The IFP diagnosis was made based on these findings (Fig. 3).

Discussion

Even though the invagination was observed rarely among the adults, 90% of the cases originate from the mass developing within the lumen ⁶. The development of small bowel obstruction might occur in acute, chronic, and intermittent manner. The abdominal pain, nausea, vomiting, and (especially in malign lesions) melena might be seen ⁷. In the present study, there were abdominal pain for 1 week and nausea and vomiting for 2 days but no melena.

Among the adults, 65-75% of the invagination origi-

nates from the benign or malign lesions, whereas 15-25% arises from the non-neoplastic factors⁸. Only 3-6% of GIS tumors are seen to be localized to small bowels. The small bowel tumors are very hard-to-diagnose unless they lead to hemorrhage or obstruction. They are generally diagnosed lately⁹. In the present case, the diagnosis was made upon observing the invagination in CT taken after the obstruction and detecting the mass during the surgical procedure.

IFP is a rare lesion of GIS identified by Vanek. It is generally asymptomatic. The symptoms are seen depending on the localization¹⁰. It causes invagination in 5-16% of the cases^{11,12}. From macroscopic aspect, it is in sessile or pedicled polypoid form. It contains inflammatory cells such as eosinophil, lymphocyte, and plasm cells¹³. It should be microscopically distinguished from gastrointestinal stromal tumor (GIST), leiomyoma, schwannoma, and metastatic malign melanoma¹⁴. IFP is the lesions having morphology similar to inflammatory myofibroblastic tumor (IMT) and GIST, and the immunohistochemical examination is required for the diagnosis. IFP is positive for CD34 and vimentin, whereas IMT is negative for CD34 and GIST is positive for CD34 and CD117 (C-KIT). In the present case, the vimentin and CD34 were found to be positive and CD117 (C-KIT) to be negative. This immune profile was interpreted in favor of IFP.

In adult population, invagination generally requires the surgical treatment. Resection and primary anastomosis are recommended^{15,16}. In invaginations developing based on the mass, there is no accepted approach to the surgical limits in the mass-caused invaginations. In the present case, the patient was undergone right hemicolectomy due to the suspicion of malignity in the mass.

In conclusion, the invagination is a cause of ileus that is rarely seen among adults and difficult-to-diagnose. The most useful method in diagnosis is the abdominal CT. It should be kept in mind for the patients, who have no abdominal surgery background and applied with the complaint of intestinal obstruction. Moreover, it generally depends on a mass. The suitable treatment method is the surgical resection depending on the mass.

RIASSUNTO

L'invaginazione è costituita da una dislocazione di un segmento prossimale dell'intestino nella porzione distale contigua. Si tratta di una evenienza rara nella popolazione adulta, e nel caso si verifica per la presenza di una neoplasia della parete intestinale del tratto invaginato. Soltanto il 3-6% dei tumori gastro-intestinali sono localizzati nell'intestino tenue, ed anche il polipo infiammatorio fibroso benigno è di rara incidenza.

Viene presentato il caso di una donna di 47 anni affetta da invaginazione ileo-ciecale determinata appunto dalla presenza di un polipo fibroso infiammatorio dell'ileo.

References

1. Zhang H: *Adult intussusception and gastrointestinal bleeding due to an isolated heterotopic pancreas*. Turk J Gastroenterol, 2013; 24:78-79.
2. Nkwam N, Desai A, Radley S: *Adult idiopathic jejuno-ileal intussusception*. BMJ Case Rep, 2010; 2010.
3. Zinkewitz K, Ve Ark: *Recurrent inflammatory fibroid polyp of cardia: a case report*. World J Gastroenterol, 2004; 10:767-68.
4. Godey SK, Diggory RT: *Inflammatory fibroid polyp of the oesophagus*. World J Surg Oncol, 2005; 30:30.
5. Changrisawat V, Ve Ark: *Unusual manifestations of gastric inflammatory fibroid polyp in a child*. World J Gastroenterol, 2004; 10: 460-62.
6. Yalamarthi S, Smith RC: *Adult intussusception: Case report and review of literature*. Postgrad Med J, 2005; 81:174-77.
7. Azar T, Berger DL: *Adult intussusception*. Ann Surg, 1997; 226:134-38.
8. Begos DG, Sandor A, Modlin IM: *The diagnosis and management of adult intussusception*. Am J Surg, 1997; 173:88-94.
9. Demiryilmaz I, Yilmaz I, Peker K, Postgil Yilmaz S, Sekban N, Albayrak Y: *Giant inflammatory fibroid polyp causing invagination: case report*. Journal of Clinical and Experimental Investigations, 2013; 4 (3): 387-89.
10. Forasté-Enríquez CF, Mata-Hernández R, Hernández-Villasenor A, Alderete-Vázquez G, Grube-Pagola P: *Intestinal obstruction in adults due to ileal intussusception secondary to inflammatory fibroid polyp: A case report*. Revista de Gastroenterología de México, 2017; 82(3):263-65.
11. Akbulut S: *Intussusception due to inflammatory fibroid polyp: A case report and comprehensive literature review*. World J Gastroenterol, 2012; 18:5745-52.
12. O'Kane A, O'Donnell M, McCavert M, et al.: *Inflammatory fibroid polyp of the ileum causing recurrent intussusception and chronic ischaemia: A case report*. Cases J, 2008; 1:244.
13. Harned RK, Buck JL, Shekitka KM: *Inflammatory fibroid polyps of the gastrointestinal tract: Radiologic evaluation*. Radiology, 1992; 182:63-66.
14. Eroglu M, Keser Ö, Tekin Y, Karaman H: *A case of inflammatory fibroid polyp causing intestinal obstruction*. Causa Pedia, 2016; 5(2): 83-87.
15. Eisen LK, Cunningham JD, Aufses AH, et al.: *Intussusception in adults: institutional review*. J Am Coll Surg, 1999; 188:390-95.
16. Verre L, Rossi R, Gaggeli I, Piccolomini A, Podzemny V, Tirone A: *Ileocecal-colonic intussusception caused by cecal adenocarcinoma: A case report*. Ann Ital Chir, 2012.